
Radiographic evaluation of periapical healing after obturation of infected root canals: an *in vivo* study

N. Katebzadeh, A. Sigurdsson & M. Trope

Department of Endodontics, University of North Carolina, Chapel Hill, North Carolina, USA

Abstract

Katebzadeh N, Sigurdsson A, Trope M. Radiographic evaluation of periapical healing after obturation of infected root canals: an *in vivo* study. *International Endodontic Journal*, **33**, 60–65, 2000.

Aim To radiographically compare periapical repair of roots with infected root canals obturated in one-step or with calcium hydroxide (Ca(OH)₂) intracanal medication in two steps.

Methodology Standardized preoperative periapical radiographs were taken of 72 roots of vital dogs' teeth. All roots were then aseptically instrumented to ISO size 45. As negative controls, 12 roots were aseptically obturated. The remaining roots were infected with dental plaque and closed. Six weeks later, apical periodontitis was radiographically confirmed in the infected roots. The roots were divided into the following groups: group 1, one-step ($n = 24$); roots were irrigated with 10 cc saline, obturated, and permanently restored. Group 2, Ca(OH)₂ ($n = 24$); roots were treated as in group 1, except that after saline irrigation Ca(OH)₂ medicament was placed in the canal 1 week before obturation. Group 3, positive control ($n = 12$); the

roots were irrigated with saline, access permanently closed but canals not obturated. Group 4, negative control ($n = 12$); previously aseptically obturated roots were permanently restored. After 6 months, standardized postoperative radiographs were obtained. Three independent evaluators blinded to the treatment groups evaluated the preoperative and postoperative radiographs. The evaluators were instructed to rate each root, based on changes on the radiographs, as failed, improved or healed.

Results Radiographically, the percentage of cases that completely healed were similar for the one-step and Ca(OH)₂ groups (35.3% vs. 36.8%). However, the Ca(OH)₂ group had fewer failed cases (15.8% vs. 41.2%) and more improved cases (47.4% vs. 23.5%) than the one-step group.

Conclusion Power statistics demonstrated that at 43 cases per group, Ca(OH)₂ treatment would be statistically superior to one-step treatment. We consider this number to be clinically important.

Keywords: healing, periapical, teeth.

Received 3 July 1998; accepted 29 June 1999

Introduction

Apical periodontitis is caused, primarily, by bacteria in the root canal space (Kakehashi *et al.* 1965, Sundqvist 1976, Bergenholtz 1974, Fabricius *et al.* 1982). Continuous stimuli from an infected root canal cause a pathologic immune response that ultimately leads to the development of a periapical lesion (Langeland *et al.* 1977, Stern *et al.* 1981). Clinically, the presence

of an inflammatory response can usually be detected by the radiographic widening of the periodontal ligament space due to the destruction of the apical soft tissue and bone by the inflammatory process (Brynolf 1967).

Radiographs, despite their limitations, provide the primary means of post-treatment evaluation of endodontic treatment and are used in most prognosis studies. Recent studies using the current standard for root canal disinfection have shown that if bacteria are removed to levels that are undetectable by bacteriological methods in use today, an extremely high success

Correspondence: Martin Trope, DMD, Department of Endodontics, School of Dentistry, CB# 7450, University of North Carolina, Chapel Hill, NC 275997450, USA.

rate in the resolution of apical periodontitis can be expected (Byström *et al.* 1987, Sjögren *et al.* 1997).

The scientifically documented procedure for the best results in canal disinfection of teeth with apical periodontitis is based on complete debridement and irrigation of the root canal during the first appointment (Byström & Sundqvist 1981, 1983), followed by the application of a $\text{Ca}(\text{OH})_2$ dressing (Byström *et al.* 1985). Obturation of the root canal is then performed at the second or a later appointment (Sjögren *et al.* 1991).

One issue frequently debated in recent years is whether conscientious cleaning by instrumentation and irrigation reduces the number of bacteria to a point where the obturation of the infected canal at the same visit will ensure successful treatment. Many practitioners claim high success rates with this technique based on patient acceptance, lack of significant flare-ups, and practice management considerations. Since current research findings indicate that one-step treatment of teeth with apical periodontitis is obturation of an infected canal in a relatively high percentage of cases, proponents of this technique rely on the lack of nutrition and space for bacterial multiplication to overcome the bacterial infection (Soltanoff 1978, Oliet 1983).

The purpose of the present study was: (i) to determine radiographically, the role of obturation alone in the healing of teeth with apical periodontitis, and (ii) to compare radiographic periapical healing of teeth with infected canals obturated with or without prior $\text{Ca}(\text{OH})_2$ disinfection.

Materials and methods

Seventy-two vital roots of 24 premolars and 24 incisors in three adult dogs were used. The dogs were anaesthetized throughout all experimental procedures. The induction of anaesthesia was achieved by IV administration of 20 mg kg^{-1} -bodyweight of Thiopental, followed by 1–2% halothane for maintenance of anaesthesia. In order to take standardized radiographs throughout the experiment, pretreatment bite blocks were fabricated using Stat-BRTM bite registration material (Kerr Corporation, Romulus, MI, USA). All procedures were performed aseptically with sterile instruments under rubber dam which was continually surface disinfected with 0.12% chlorhexidine.

Each dog was treated with all four treatment methods. After coronal pulp exposure, all roots were instrumented to ISO size 45. Twelve randomly assigned roots were not infected to serve as negative controls. The remaining 60 roots were infected with

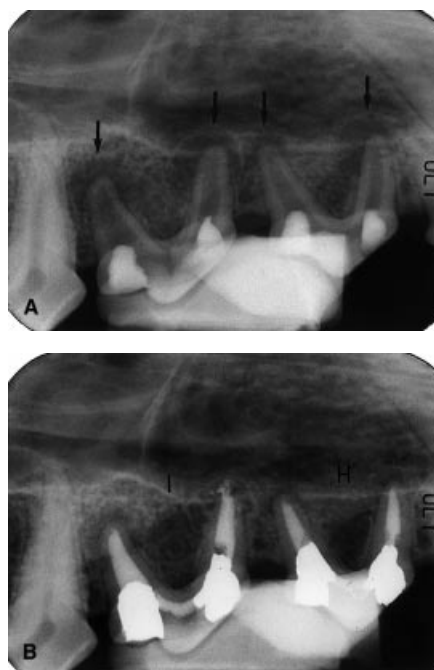

Figure 1 (A) Radiograph confirming the presence of apical radiolucencies on each root of the treated premolars (arrows). (B) Radiograph of the same teeth, 6 months postobturation showing healing (H) on one tooth or improvement (I) on the other.

dental plaque and restored coronally with IRM (Caulk Co., Dentsply, Milford, DE, USA.). Six weeks later apical periodontitis was confirmed radiographically in the infected teeth (Fig. 1a). Anaerobic cultures were obtained and confirmed bacterial infection in teeth with apical periodontitis. The teeth were then randomly assigned to four groups as follows: group 1, one-step ($n = 24$); each root was irrigated with 10 mL saline, dried with paper points, and obturated with gutta-percha and Roth 811 sealer (Roth International Ltd., Chicago, IL, USA) with the cold lateral condensation technique, and coronally sealed with IRM. Group 2, $\text{Ca}(\text{OH})_2$ ($n = 24$); teeth were treated as in group 1, except that after saline irrigation, $\text{Ca}(\text{OH})_2$ dressing was placed in the canals using a lentulo spiral filler and the teeth were coronally sealed with IRM for 1 week. After 1 week, the teeth were obturated as in group 1. Group 3, positive control ($n = 12$); each root was irrigated with 10 mL of saline, the canals were not obturated but left empty, and the access cavities were sealed with IRM. Group 4, negative control ($n = 12$); irrigated with 10 mL sterile saline, obturated as in the other groups and coronally sealed with IRM. At the time of obturation of group 2, temporary restorations from all teeth in all groups were replaced

with permanent amalgam restorations. The dogs were fed a soft diet for 3–5 days immediately after the dental procedures.

At the end of the observation period (6 months), standardized radiographs were again taken. Three independent evaluators, blinded to the treatment groups, compared the preoperative and postoperative radiographs. They rated the roots, in cases where radiolucencies were discernible before treatment, according to the following predetermined criteria:

- Healed = Normal pattern of trabecular bone and normal width of PDL space (Fig. 1b)
- Improved = Reduction in lesion size (Fig. 1b)
- Failed = Increase or no change in the lesion size (Fig. 2a,b)
- X = Unreadable radiograph because of technical errors such as cone cut

A final rating was decided upon, based on agreement on at least two ratings out of three, and was called the

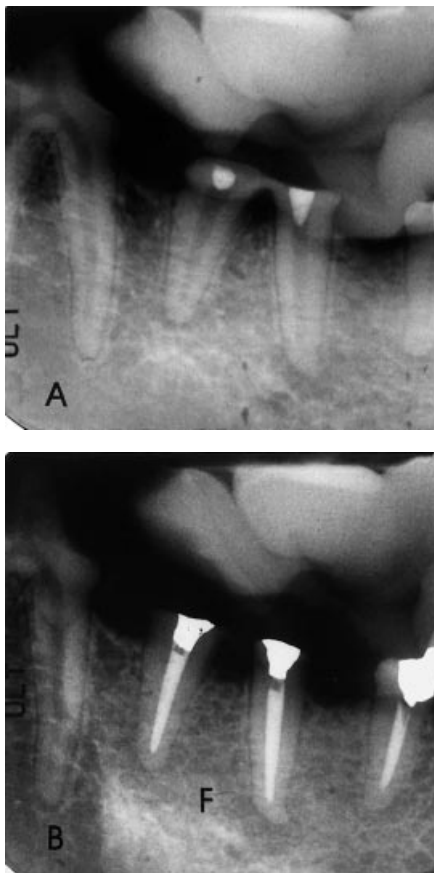


Figure 2 Radiographic presentation of lesions assessed as failed (F). (A) Immediate postop; (B) six-month follow-up.

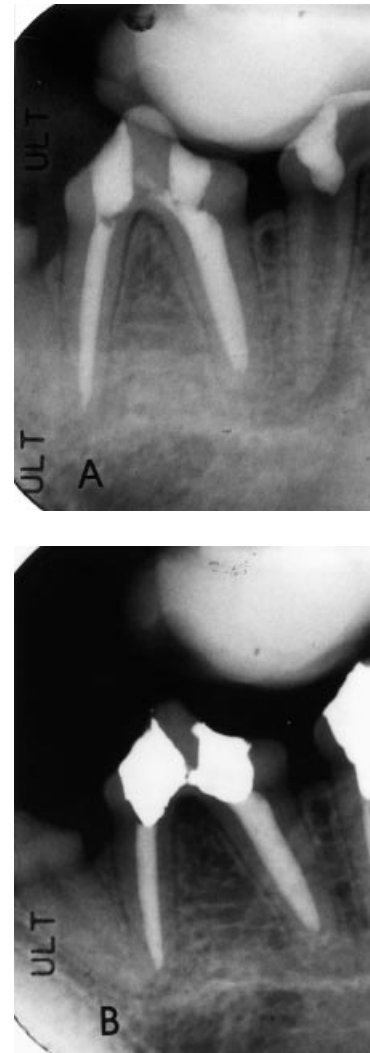


Figure 3 Radiographic follow-up of negative control (vital pulpectomy). (A) Immediate postop; (B) six-month follow-up.

'final rating'. The final ratings were used for statistical analysis.

Statistical analysis

To assess rater agreement, the Kappa statistic was used. This statistic was first computed between each pair of observers and then averaged to get an overall level of agreement amongst the raters.

A chi-squared test was used to see if there was an overall difference between the groups. The treatment groups were then compared pair-wise. The level of significance was set at $P < 0.05$. Power analysis calculations were performed to determine the sample size at

Table 1 Proportion of failed, improved, and healed ratings for the 3 treatment groups. There was a significant overall difference (Chi-square of 11.847, $df = 2$, $P = <0.01$). (Radiographic Evaluation)

	% failed	% Improved	% healed
(+) control	90	10	0.0
One-step	41.2	23.5	35.3
Ca(OH) ₂	15.8	47.4	36.8

which statistically significant differences would be demonstrated.

Results

Nine roots were rated X (unreadable) and six roots did not develop radiolucencies and were excluded from the study. Of 57 roots, 17 were in group 1 (one-step), 19 in group 2 (Ca(OH)₂), 10 in the positive control, and 11 in the negative control groups.

The Kappa statistics showed good agreements between the three evaluators with kappa = 0.60 for overall agreement value. This value reports the agreement prior to the final rating determination.

To compare the treatments for differences in proportion healed (H), improved (I), or failed (F), the negative controls were excluded, because they did not theoretically have a chance to heal (Fig. 3a,b). The chi-squared test was conducted on 46 remaining roots. The overall results for the three treatment groups are summarized in Table 1. There was a significant overall difference amongst the groups (chi-square of 11.847, $d.f. = 2$, $P = 0.01$). Pair wise comparison showed that

the positive control group was significantly different from one-step and Ca(OH)₂ group, but the one-step and Ca(OH)₂ groups were not significantly different from each other.

The bar graph in Figure 4 illustrates the distribution of the positive control group, group 1 (one-step), and group 2 (Ca(OH)₂) within the radiographic rating categories. None of the radiographs in the positive control group were rated 'healed', whilst almost equal numbers of radiographs in groups 1 and 2 were rated 'healed' (35.3% and 36.8%, respectively). The positive control group showed the most 'failed' rating (90%) whilst the Ca(OH)₂ group showed the least (15.8%). The one-step group received 41.2% 'failed' rating. A total of 47.4% of radiographs in the Ca(OH)₂ group were rated as 'improved' compared to 23.5% in the one-step group. The *P*-values for these pair-wise comparisons are shown in Table 2. A power analysis calculation was performed to compare the one-step and Ca(OH)₂ groups in the failed cases versus improved and healed cases (combined). These calculations demonstrated that if the same trend in the results continued, a sample size of at least 43 in each group would demonstrate statistical differences between the one-step and Ca(OH)₂ groups, at 0.05 level of significance.

Discussion

Using the present model, infecting the root canal space resulted in development of apical radiolucencies in most cases. These results show the effectiveness of the model and confirm the role of canal infection in the

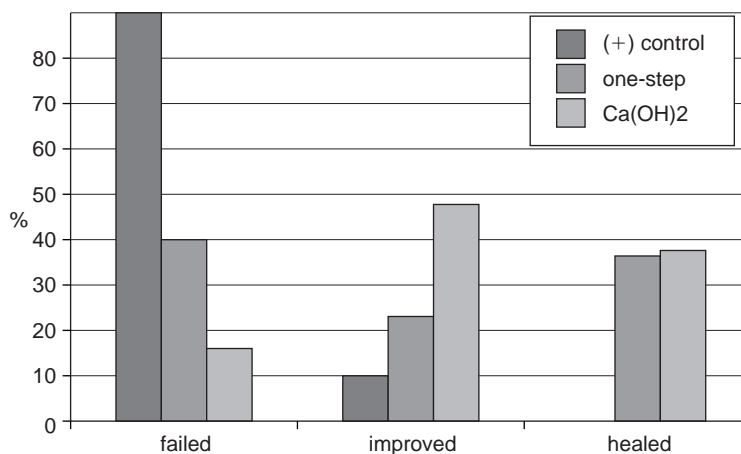


Figure 4 Percentage of failed, improved and healed ratings for the three treatment groups.

Table 2 Pair-wise comparison of treatment groups. (+) control was significantly different from one-step and Ca(OH)₂ groups, but the latter two groups were not significantly different from each other. (Radiographic Evaluation)

	Chi-squared	d.f.	P-value
(+) control vs. one-step	6.331	1	<0.05
(+) control vs. Ca(OH) ₂	12.473	1	<0.001
one-step vs. Ca(OH) ₂	1.001	1	<0.05

induction and persistence of apical periodontitis. The infected status of the canals was also confirmed by obtaining random bacterial cultures from the root canals.

Our inclusion criteria were such that only the radiographs that had a chance for healing, improving, or failing could be included in the analysis. Therefore, the negative control group that was not initially infected and the radiographs with a preop and postop rating of 'no lesion' had to be excluded. Once these exclusions were done, 46 roots were left to be analysed.

In a few cases, lesions were not radiographically discernible and the teeth could not be used for the study. This finding is not surprising considering the limitations of currently used radiographic techniques. In fact, the teeth described in this study were also evaluated histologically (Katebzadeh *et al.*, *in press*) and periapical inflammation was histologically present in these cases as well.

To evaluate the role of obturation alone in periapical repair, it was necessary to obturate canals known to be infected to simulate the approximately 40–60% of all necrotic cases that are still infected when they are obturated after a one-step procedure (Byström & Sundqvist 1983). To eliminate the instrumentation step as a variable, the canals were instrumented prior to infection. Bacteria were then introduced into the canals that were already enlarged and therefore, instrumentation could not play a role in the eventual periapical healing.

The highest failed ratings (90%) were recorded in the positive control group where the infected canals were not obturated. This finding clearly demonstrates that obturation is an important step in endodontic treatment. Interestingly, 10% of the radiographs in the negative control group (noninfected canals that were aseptically obturated) received the 'improved' rating. This observation may be due to 'temporary failures' which develop as a result of mechanical irritation of the periapical tissues. Instrumentation and obturation

may both be involved in irritation and temporary disruption of the supporting periodontium. In addition, the disruption of the periodontium may be due to coronal leakage and contamination of the root canal system (Ray & Trope 1995, Madison & Anderson 1992).

In the one-step group, 35.3% of the cases showed complete radiographic healing. These results confirm that obturation alone is an important factor in successful endodontic therapy. By occupying space and reducing the substrate for bacterial proliferation, obturation plays a key role in healing of apical periodontitis. On the other hand, the 41.2% failures in the one-step group demonstrate that the mechanical barriers alone (obturation material) are not sufficient to obtain predictably successful results.

The lowest failed ratings (15.8%) were recorded in the Ca(OH)₂ group where 1 week of Ca(OH)₂ dressing was placed in the canal prior to obturation. A large number of cases in the Ca(OH)₂ group were in the improved category (47.4%) and not in the 'extreme' categories of healed or failed. Because of this fact, it was not possible to get statistical differences between the one-step and the Ca(OH)₂ groups. It appears that the six-month follow up was not sufficient for radiographic assessment, and if we had waited for a longer period, probably more cases would have entered the 'extreme' categories.

It was felt that lack of statistical significance could also be due to the small sample size. When one-step and Ca(OH)₂ groups are compared in the failed versus improved and healed cases (combined) the difference is large, but not statistically significant. A power analysis calculation demonstrated that if the same trend in the results continued, a sample size of at least 43 would be required to demonstrate a statistically significant difference between the one-step and Ca(OH)₂ groups ($P < 0.05$).

The high clinical success rate that is expected from one-stepping is probably due to the fact that clinical evaluations are symptomatic and radiographic. The inflammation seen histologically cannot be considered in most prognosis studies (Strindberg 1956, Sjögren *et al.* 1990). Brynolf (1967) found only 7% histologic success in root canal treated teeth. She suggested that in order to correlate histologic and radiographic material properly, the histologic and radiographic appearance of the apical areas must be examined independently. In fact, as expected, we found a much lower success rate for the teeth when evaluated histologically (Katebzadeh *et al.* 1999).

Overall, the best results were obtained when the infected canals were disinfected with Ca(OH)₂ before obturation and this treatment form should be performed as a routine in cases with apical periodontitis. Our results agree with other recent controlled studies that confirm the clinical benefits of reducing the number of bacteria in the root canal before obturation (Byström *et al.* 1985, Sjögren *et al.* 1997). Trope *et al.* (1999), showed superior clinical results for Ca(OH)₂ disinfection compared to one-step treatment of teeth with apical periodontitis, in a prospective radiographic study on humans.

Improvement of radiographic techniques is necessary for obtaining accurate information from our radiographic assessments. Ideally, radiographs should provide information that truly represents the histologic condition of a given area. New imaging modalities, such as Tuned-Aperture Computed Tomography (TACT) that view the object in 'slices', somewhat similar to histologic sections, may overcome some of the current limitations of radiographic assessments (Webber *et al.* 1997). Digital subtraction may also allow detection of small osseous changes that are not detectable by conventional radiographic techniques (Tyndall *et al.* 1990).

Acknowledgement

This study was supported in part by a grant from the Endodontic Research Foundation of the American Association of Endodontists.

References

- Bergenholtz G (1974) Microorganisms from necrotic pulps of traumatized teeth. *Odontologisk Revy* **25**, 347–51.
- Brynolf I (1967) A histological and roentgenological study of the periapical region of human upper incisors. *Odontologisk Revy* **18** (Suppl. II), 1–176.
- Byström A, Cleasson R, Sundqvist G (1985) The antibacterial effect of camphorated paramonochloro-phenol, camphorated phenol, and calcium hydroxide in the treatment of infected root canals. *Endodontics and Dental Traumatology* **1**, 170–5.
- Byström A, Happonen R-P, Sjogren U, Sundqvist G (1987) Healing of periapical lesions of pulpless teeth after endodontic treatment with controlled asepsis. *Endodontics and Dental Traumatology* **3**, 58–65.
- Byström A, Sundqvist G (1981) Bacteriological evaluation of the efficacy of mechanical root canal instrumentation in endodontic therapy. *Scandinavian Journal of Dental Research* **89**, 321–8.
- Byström A, Sundqvist G (1983) Bacteriological evaluation of the effect of 0.5% sodium hypochlorite in endodontic therapy. *Scandinavian Journal of Dental Research* **55**, 307–12.
- Fabricius L, Dahlen G, Ohman AE, Moller AJR (1982) Predominant indigenous oral bacteria isolated from infected root canals after varied times of closure. *Scandinavian Journal of Dental Research* **90**, 133–44.
- Kakehashi S, Stanley HR, Fitzgerald RJ (1965) The effect of surgical exposure of dental pulps in germ-free and conventional laboratory rats. *Oral Surgery, Oral Medicine and Oral Pathology* **20**, 340–9.
- Katebzadeh N, Hupp J, Trope M (1999) Histologic periapical repair following obturation of infected root canals in dogs. *Journal of Endodontics* **25**, 364–8.
- Langeland K, Block RM, Grossman LI (1977) A histopathologic and histobacteriologic study of 35 periapical endodontic surgical specimens. *Journal of Endodontics* **3**, 8–23.
- Madison S, Anderson RW (1992) Medications and temporaries in endodontic treatment. *Dental Clinics of North America* **36**, 343–56.
- Oliet S (1983) Single-visit endodontics: a clinical study. *Journal of Endodontics* **9**, 4–7.
- Ray HA, Trope M (1995) Periapical status of endodontically treated teeth in relation to the technical quality of the root filling and the coronal restoration. *International Endodontic Journal* **28**, 12–8.
- Sjogren U, Figdor D, Persson S, Sundqvist G (1997) Influence of infection at the time of root filling on the outcome of endodontic treatment of teeth with apical periodontitis. *International Endodontic Journal* **30**, 397–406.
- Sjogren U, Figdor D, Spangberg L, Sundqvist G (1991) The antimicrobial effect of calcium hydroxide as a short-term intracanal dressing. *International Endodontic Journal* **24**, 119–25.
- Sjogren U, Hagglund B, Sundqvist B, Wing K (1990) Factors affecting the long-term results of endodontic treatment. *Journal of Endodontics* **16**, 498–504.
- Soltanoff W (1978) A comparative study of the single-visit and the multiple-visit endodontic procedure. *Journal of Endodontics* **4**, 9–14.
- Stern MH, Dreizen S, Mackler BF, Selbst AG, Levy BM (1981) Quantitative analysis of cellular composition of human periapical granuloma. *Journal of Endodontics* **7**, 117–22.
- Strindberg LZ (1956) The dependence of the results of pulp therapy on certain factors. An analytic study based on radiographic and clinical follow up examinations. *Acta Odontologica Scandinavica* **14** (Suppl. 21), 1–175.
- Sundqvist G (1976) Bacteriological studies of necrotic dental pulps. (Umea University Odontological Dissertations No. 7). Sweden: University of Umea.
- Trope M, Delano E, Orstavik D (1999) Endodontic treatment of teeth with apical periodontitis: single- vs. multi-visit treatment. *Journal of Endodontics* **25**, 245–50.

Tyndall DA, Kapa SF, Bagnell CP (1990) Digital subtraction radiography for detecting cortical and cancellous bone changes in the periapical region *Journal of Endodontics* **16**, 173–8.

Webber RL, Horton RA, Tyndall DA, Ludlow JB (1997). Tuned Aperture Computed Tomography (TACT tm). Theory and application for three-dimensional dento-alveolar imaging. *Dentomaxillofacial Radiology* **26**, 53–62.