

CLINICAL AID

Post Removal prior to Retreatment

Pierre Machtou, DCD, DSO, Philippe Sarfati, DCD, and Anna Genevieve Cohen, DCD, MsD

Removing posts from root canals prior to endodontic retreatment is often a challenge. The Gonon post removing system (Thomas Extracteur De Pivots; FFD-M-Pneumat, Bourges, France) is safe and efficient and can be used for anterior, bicuspid, and even molar teeth. The Gonon system is illustrated with one clinical case.

Endodontic retreatment is one of the most challenging areas in dentistry (1). The procedure is further complicated when the clinician is called upon to remove a post prior to the retreatment (2). Because post removal can jeopardize the remaining tooth structure (3), most clinicians avoid the procedure and treat surgically.

In selected cases, however, conventional endodontic retreatment is a better alternative than surgical endodontics. A surgical approach may be compromised if irritants within the tooth are not eliminated. Also, surgery may be inadvisable due to various medical and anatomical considerations. Furthermore, endodontic retreatment is obviously less traumatic.

There are a variety of techniques (3-6) to remove posts. The objectives, however, are the same. The procedure should be simple and expedient and the integrity of the remaining tooth structure should not be jeopardized.

The purpose of this article was to present one clinical case (Fig. 1) illustrating the effectiveness of the Gonon post removing system (Fig. 2) which has been used extensively in France.

TECHNIQUE AND CLINICAL CASE

The principle of this instrument is comparable to a corkscrew. The post and the tooth are separated by pitting the tooth against the post and creating enough force to overcome the bond.




FIG 2. The Gonon post remover kit.

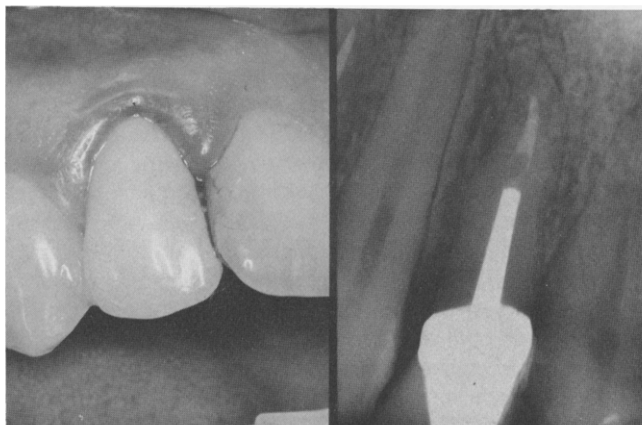


FIG 1. Poor endodontic treatment and unhealthy periodontism on tooth 7.

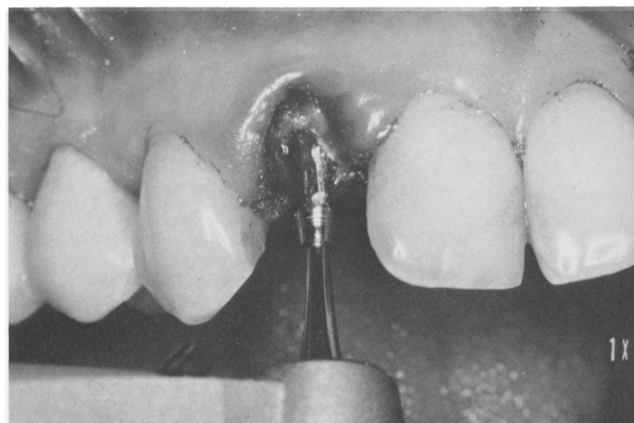


FIG 3. Tapering of the head of the post.

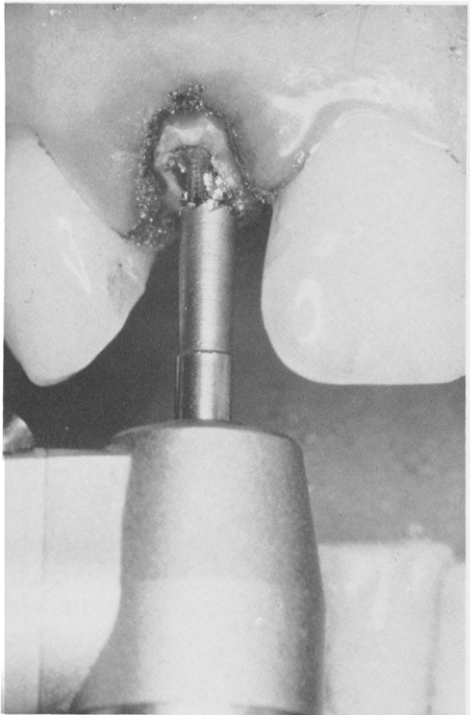


FIG 4. Use of the trephine.

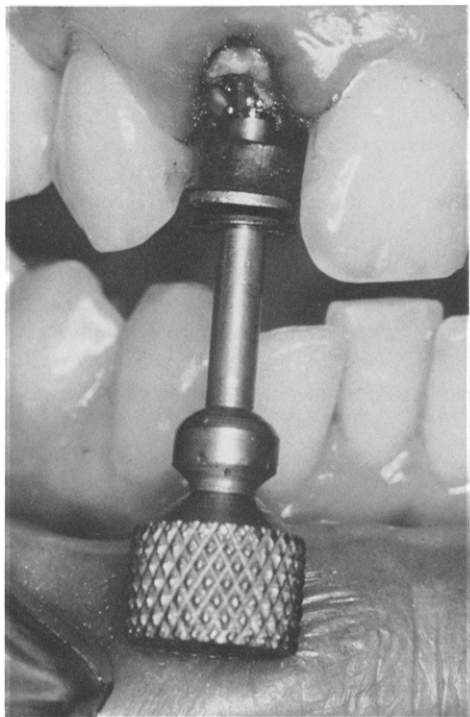


FIG 5. Threading of the post.

1. The first step is to free the head of the post from the coronal tooth structure. All restorations including crowns must be removed.

Circumferential preremoval of the core may be achieved using a tapered diamond bur at high speed.

2. An ultrasonic device is useful to vibrate the post and disintegrate the cement.

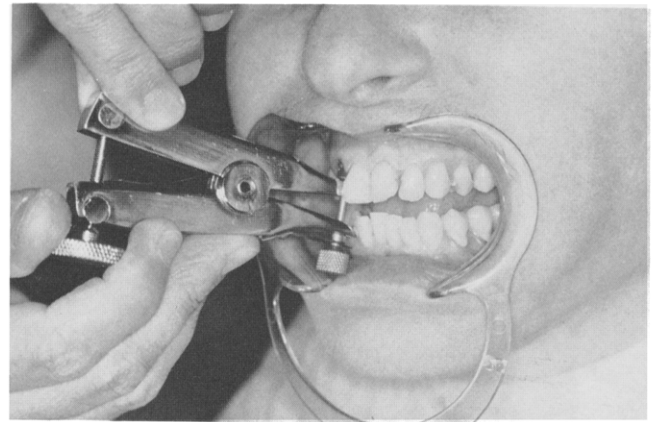


FIG 6. Positioning of the beaks of the Gonon pliers.

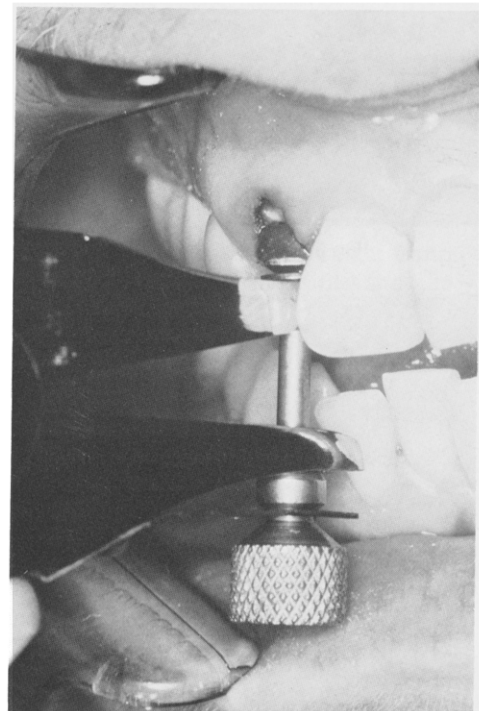


FIG 7. Extracting pliers on the threaded mandrel.

3. In order to facilitate the centering of the trephine (Fig. 3), a special bur included in the Gonon kit is used to taper the protruding head of the post.

4. The high strength trephine is used to bore and gauge the protruding post to the exact size of a corresponding mandrel which is specially manufactured to thread the post (Fig. 4).

5. Before the mandrel is screwed onto the post, three rings are positioned onto its shank (Fig. 5). This acts to cushion the mandrel and to spread the forces onto the root surface as the post is being extracted.

6. The extracting pliers are fixed on the mandrel (Figs. 6 and 7) and the jaws of the pliers are expanded by tightening the knurled knob. This procedure will separate the post from the tooth quickly and safely (Figs. 8 and 9) facilitating endodontic retreatment (Fig. 10).

Sometimes the space between the adjacent teeth is smaller than the width of the jaws. This problem may be resolved by




Fig 8. The post removed.

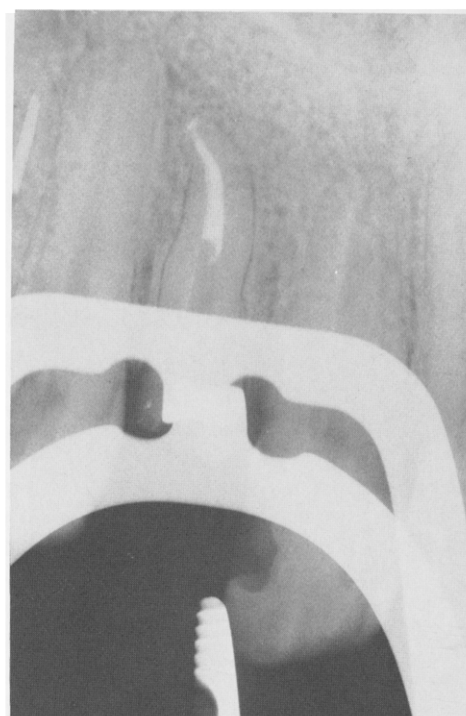

Fig 10. Endodontic retreatment completed.

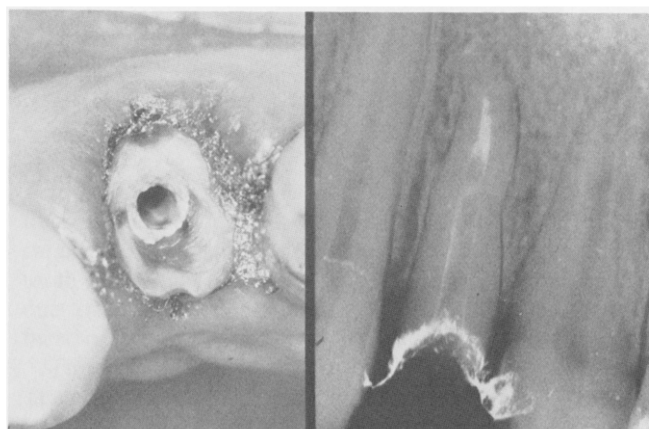


Fig 9. The empty canal.

slipping a hollow tube included in the package into the "long" threaded mandrel.

DISCUSSION

Techniques advocating troughing or ditching tooth structure to remove posts should be discontinued. Attempts to reduce posts using high-speed burs should also be abandoned due to their predisposition to root perforations or overenlarging the canal, inviting root fracture.

Most devices manufactured to extract posts are inconvenient or have limited applications (4–6). In most instances, the Gonon post remover may be used safely and efficiently. It is extremely adaptable to anteriors and bicuspids. In molar areas where the intermaxillary distance is limited, post removal may be accomplished without the use of the pliers. The kit is also available with trephines which have counter clockwise threading. These trephines will facilitate the removal of screw and threaded posts.

Text revision by Dr. Michael J. Scianamblo, assistant professor of endodontics, School of Dentistry, University of California, San Francisco, CA.

Dr. Machtou is associate professor and Drs. Sarfati and Cohen are instructors, Department of Endodontics, Paris VII University, Faculty of Dental Surgery, Paris, France.

References

1. Schilder H. Passages. *J Endodon* 1986;12:177.
2. Friedman S, Stabholz A. Endodontic retreatment. Case selection and technique. Part I. Criteria for case selection. *J Endodon* 1986;12:28–33.
3. Gerstein H. Techniques in clinical endodontics. Philadelphia: WB Saunders, 1983;324–45.
4. Warren SR, Guttman JL. Simplified method for removing intradicular posts. *J Prosthet Dent* 1979;42:353–6.
5. Bando E, Kawashima T, Tiu IT, Kubo Y, Nakano M. Removing dowels in difficult teeth. *J Prosthet Dent* 1985;54:34–6.
6. Williams VD, Bjorndal AM. The Masseran technique for the removal of fractured posts in endodontically treated teeth. *J Prosthet Dent* 1983;49:46–8.