

Periodontal healing after bonding treatment of vertical root fracture

Sugaya T, Kawanami M, Noguchi H, Kato H, Masaka N. Periodontal healing after bonding treatment of vertical root fracture. *Dent Traumatol* 2001; 17: 174–179. © Munksgaard, 2001.

Abstract – Vertical root fractures lead to advanced periodontal breakdown with deep periodontal pockets and vertical bone defects. The purpose of this study is to evaluate clinically the periodontal healing of root fracture treatment using adhesive resin cement. In 22 patients, 23 teeth with vertical root fractures were treated with 4-META/MMA-TBB resin cement. Eleven fractured roots were bonded through the root canal (group A) and 12 fractured roots were bonded extra-orally and replanted (group B). All teeth were then restored with full cast crowns ($n=20$) or coping ($n=3$). Mean probing depth was 6.6 mm at pre-treatment and 4.4 mm 6 months after the treatment in group A, and 7.4 mm and 4.6 mm, respectively, in group B. Bleeding scores were 100% at pre-treatment and 36.4% after 6 months in group A and 91.7% and 8.3%, respectively in group B. Radiographic bone level was 56.8% at pre-treatment and 59.1% after 6 months in group A, and 18.8% and 29.2%, respectively, in group B. Two roots of group A and three roots of group B were extracted due to refracture, deterioration of periodontal inflammation, mobility, and luxation. The remaining roots ($n=18$) presented no discomfort to the patients and there was no deterioration of periodontal conditions over a mean period of 33 months (range 14–74 months) in group A and over a mean period of 22 months (range 6–48 months) in group B. There was no ankylosed teeth nor was any root resorption detected. The results suggested that the treatment of vertical root fracture using 4-META/MMA-TBB resin has good prognostic possibilities.

Vertical root fractures lead to advanced periodontal breakdown with pain, gingival swelling, fistulas, tooth mobility, deep localized periodontal pockets, and vertical bone defects. If a vertical root fracture occurs in a multi-rooted tooth, the tooth can be conserved by resecting the root (1). In a single-rooted tooth, however, a vertical fracture usually has a hopeless prognosis and results in extraction (2, 3).

Different approaches have been attempted to treat the vertical root fractures. Oliet (4) extracted three vertically fractured teeth, cemented the segments with cyanoacrylate extra-orally and replanted them. Three months later, one of the teeth was extracted due to refracture. Fifteen months later, two of the teeth were

still comfortable and functional, but the long-term prognosis was judged poor. Trope & Rosenberg (5) extracted a vertically fractured maxillary second molar, bonded the two segments with glass-ionomer bone cement and replanted the molar in conjunction with an e-PTFE membrane. After 1 year the tooth remained functional. Selden (6) reported a two-stage surgical procedure that incorporated bonding with silver glass-ionomer cement, placement of a bone graft material, and GTR therapy. Five out of six roots failed within 2–11 months. The periodontal health of one root was maintained for 12 months but the vertical fracture deteriorated into a split. Masaka (7) bonded the fractured segments of six teeth using

**Tsutomu Sugaya,
Masamitsu Kawanami,
Hiroshi Noguchi, Hiroshi Kato,
Nobuo Masaka***

Periodontology and Endodontology, Department of Oral Health Science, Hokkaido University Graduate School of Dentistry, Sapporo, Japan

*Currently in private practice, Tokyo, Japan

Key words: vertical root fracture; adhesive resin cement; periodontal healing; replantation

Tsutomu Sugaya, Periodontology and Endodontology, Department of Oral Health Science, Hokkaido University Graduate School of Dentistry, Kita 13 Nishi 7, Kita-Ku, Sapporo 0608586, Japan.
Fax: +81 11 706 4334.

e-mail: sugaya@perio2.den.hokudai.ac.jp

Accepted 3 October 2000

4-META/MMA-TBB resin through the root canals. Five out of 6 roots were functional for more than 10 years. Twenty-eight roots were extracted and bonded extra-orally and replanted. Twenty-four roots (out of 28) were functional for 5 years.

The long-term prognosis of the bonding procedure using 4-META/MMA-TBB resin for vertical root fracture seems to be quite good, but the periodontal healing response to the procedure using 4-META/MMA-TBB has not yet been sufficiently clarified. The purpose of this study is to evaluate the clinical response and healing of the periodontal tissue after bonding the fractured teeth with 4-META/MMA-TBB resin through the root canal or extra-orally.

Material and methods

Twenty-two patients, 5 males and 17 females, of an average age of 57.5 years (range 31–75), with 23 teeth exhibiting vertical root fractures participated in this study. All were informed of the experimental procedure and consented to participate in the clinical project. Tooth types were incisors (*n*=4), canines (*n*=6), premolars (*n*=6) and molars (*n*=7). In eight cases incomplete fractures were detected on one of the root surfaces and in 15, complete fractures extended through the root (Table 1).

Clinical assessments

Following removal of the restoration and post, probing depth, bleeding on probing, tooth mobility, and radiographic bone level were assessed (Figs. 1, 2).

Probing depth was measured with a periodontal probe (PCP-11®, Hu-Friedy, Chicago, IL, USA) along the fracture sites. The deepest probing depth was recorded.

Bleeding on probing was recorded while measuring probing depth.

Clinical assessment of tooth mobility was done according to Miller's mobility index (8).

The radiographic bone level was assessed by the following ratio: distance from the root apex to the

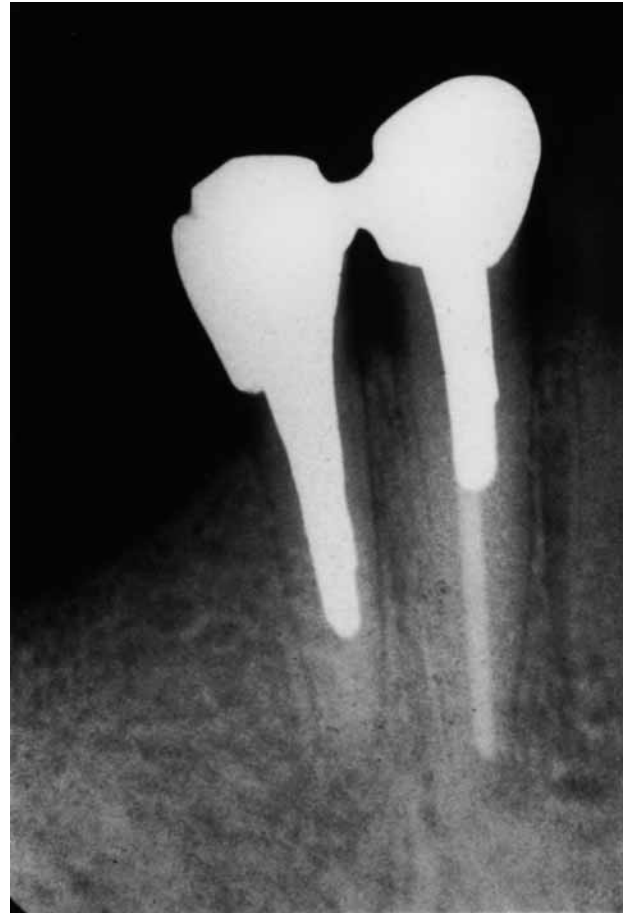

Fig. 1. Pre-treatment radiograph of mandibular right first premolar with vertical root fracture shows no bone loss.

bottom of the bone defect divided by the total root length on dental radiograph.

Treatment methods

The fractured teeth were divided into two groups: group A: intra-orally bonded, and group B: extra-orally bonded.

In group A (*n*=11), the fractured root was bonded through the root canal without tooth extraction. Firstly, the root canal was prepared, and an impression was taken to make the cast-post after completion of the endodontic treatment. The cast-post was then prepared. 6-Amiono-1,3,5-triadine-2,4-ditiol (V-primer®, Sun Medical, Shiga, Japan) was applied to the cast-post; the dentin was etched with 10% citric acid and 3% ferric chloride for 5 s, then washed and dried. These procedures were carried out according to the manufacturer instructions. The root canal was filled with 4-META/MMA-TBB resin (Super-Bond C&B®, Sun Medical) and the cast-post inserted. The fractured segments were held in contact with the forceps for the required setting time in order to prevent

Table 1. Distribution of the treated teeth

	Group A (<i>n</i> =11)	Group B (<i>n</i> =12)
Tooth type	Incisor: 2 Canine: 4 Premolar: 3 Molar: 2	Incisor: 2 Canine: 2 Premolar: 3 Molar: 5
Fracture type	Complete: 8 Incomplete: 3	Complete: 7 Incomplete: 5
Restoration after bonding	Full cast crown: 5 Fixed bridge: 5 Coping: 1	Full cast crown: 5 Fixed bridge: 5 Coping: 2

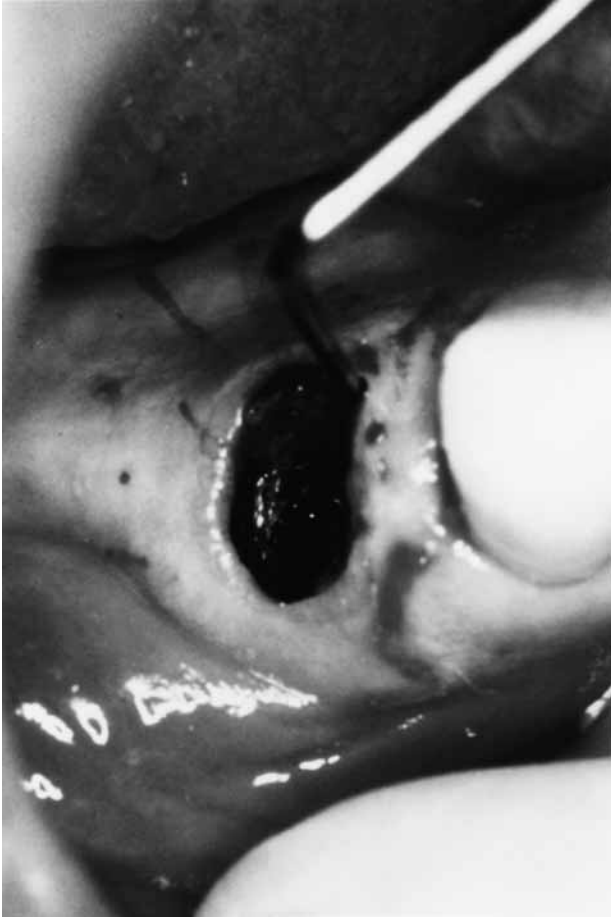


Fig. 2. Pre-treatment oral photograph shows 8 mm probing depth along the fracture site on the mesio-lingual surface.

separation. The root surface was debrided by hand and ultrasonic scaler if suppuration and/or bleeding on probing was detected during re-examination after 1–2 weeks.

In group B ($n=12$), the fractured root was extracted under local anesthesia using only forceps (Fig. 3). The internal aspect of the root canal was cleaned with a sterile bur extra-orally. The fracture sites of the root segments were cleaned, etched with citric acid, washed, dried and bonded using 4-META/MMA-TBB resin (Fig. 4). Two segments were pressed together with forceps and placed in saline for the time required for curing. The resin overflow was removed and the root surface was debrided carefully with a sterile hand instrument and/or a bur without injury to the periodontal ligament. After removing the granulation tissues from the alveolar socket, the bonded root was replanted in its original position (Fig. 5). All these procedures were performed in 30 min. Thereafter the replanted root was fixed to the proximal teeth using 4-META/MMA-TBB resin for 2–6 weeks. Then cast-post was made and cemented using 4-META/MMA-TBB resin.

In group A, of 11 teeth, 5 were restored with full-cast crowns, 5 with full-cast crowns splinted to fixed bridges and 1 with coping 1–3 months after the bonding. In group B, of 12 teeth, 5 were restored with full-

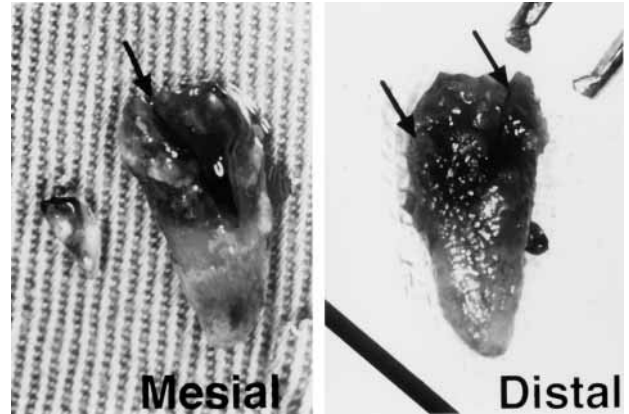


Fig. 3. A. Photograph shows the mesial surface of the extracted premolar with the fractured segment (arrow). B. The fracture line (arrow) is detected on the distal surface.



Fig. 4. The fractured root was bonded extra-orally using 4-META/MMA-TBB resin. A gutta-percha point was inserted into the root canal in order to guide the post preparation.

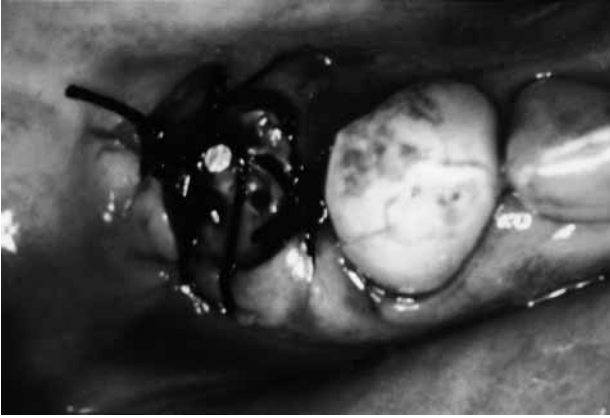

Fig. 5. The replanted root was sutured in the gingiva and then fixed to the proximal tooth with 4-META/MMA-TBB resin.

cast crowns, 5 with full-cast crowns splinted to fixed bridges and 2 with copings 2–4 months after the replantation (Table 1).

Re-examination

The same clinical examinations as carried out pre-treatment were performed after 6 months. In addition, any change in tooth mobility and percussion sound, and disappearance of the periodontal ligament space on the radiograph were examined for the diagnosis of ankylosis (9). All the patients were recalled at an interval of 2–6 months for maintenance (Fig. 6), which consisted of reinforcement of oral hygiene, and supra- and subgingival prophylaxis.

Statistical analysis

Statistical analysis was performed using Stat View® (Abacus Concepts, CA, USA). The effects of treatment on probing depth, mobility and bone level were analyzed using the Wilcoxon signed-rank test, comparing pre-treatment values with the 6-month recordings. Frequencies of bleeding on probing were compared using the Chi-square test.

Results

All the bonded teeth were conserved up to 6 months after treatment.

Group A

The mean probing depth along the fracture sites was 6.55 mm at pre-treatment and 4.36 mm 6 months after the treatment. The statistical difference was significant ($P < 0.01$, Wilcoxon signed-rank test) (Table 2). All (100%) of the sites demonstrated bleeding on probing at pre-treatment and 36.4% demonstrated

bleeding at 6 months after the treatment; the difference was also significant ($P < 0.05$, Chi-square test). Mean tooth mobility was 0.55 at pre-treatment and 0.18 after 6 months (not significant, Wilcoxon signed-rank test). Radiographic bone level was 56.8% and 59.1% at pre-treatment and after 6 months, respectively (not significant, Wilcoxon signed-rank test).

After 6 months, one tooth was extracted due to a deep periodontal pocket, deterioration of bone defect and discomfort. Another tooth was extracted due to refracture after 11 months. The remaining teeth presented no discomfort and there was no deterioration of periodontal conditions over a mean period of 33 months (range 14–74 months) (Table 3). There were no ankylosed teeth or root resorption.

Group B

The mean probing depth along the fracture sites at pre-treatment (7.42 mm) decreased significantly at 6 months after the treatment (4.58 mm) ($P < 0.01$, Wilcoxon signed-rank test) (Table 2). Bleeding was demonstrated at 91.7% of the sites on probing at pre-

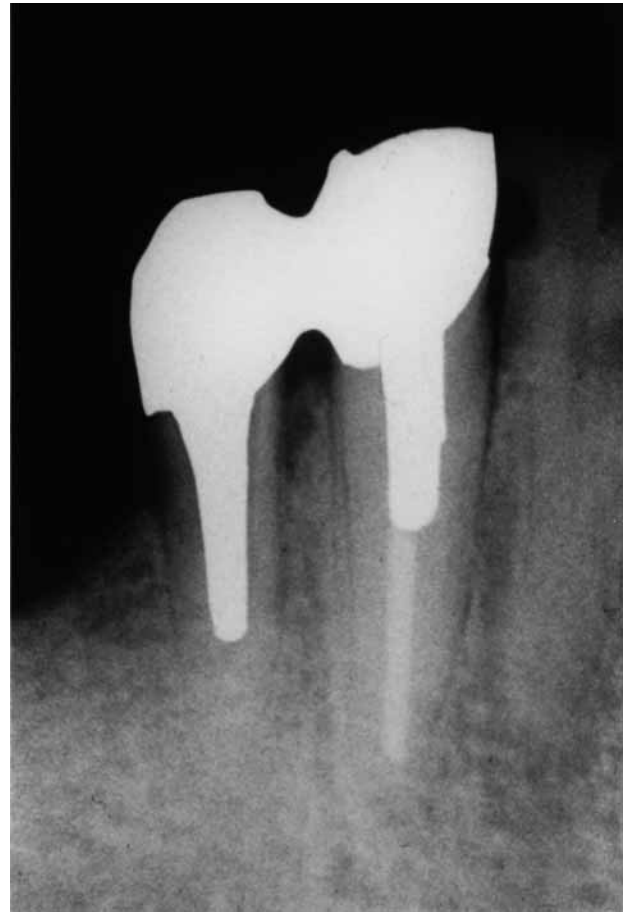

Fig. 6. Five years later. Radiograph shows no bone loss. The probing depth was 3 mm.

treatment and this decreased to 8.3% at 6 months after the treatment. The difference was significant ($P<0.01$, Chi-square test). Mean tooth mobility was 1.27 at pre-treatment and 0.33 after 6 months (not significant, Wilcoxon signed-rank test). Radiographic bone level was 18.8% at pre-treatment and 29.2% after 6 months (a significant difference, $P<0.05$, Wilcoxon signed-rank test).

After 6 months, one tooth was extracted due to deep periodontal pocket and increased mobility. Two more teeth were extracted due to refracture after 28 and 29 months. The rest of the teeth presented no discomfort to the patients and no deterioration of periodontal conditions was detected over a mean period of 22 months (5–48 months) (Table 3). There were no ankylosed teeth or root resorption.

Discussion

Many procedures have been attempted for the treatment of the vertically fractured root (4–7, 10–12). These case reports suggested that sealing the fracture and preventing the refracture might be a successful treatment modality for vertical root fracture. This clinical study examined the periodontal response after sealing the vertical fracture intra- and extra-orally

with a suitable bonding system using 4-META/MMA-TBB resin.

The resin has been selected for bonding the vertical fracture as it yields a high tensile strength (13), is bio-compatible (14–16) and is unaffected by blood contamination (13).

The frequency of bleeding on probing in groups A and B was significantly improved 6 months after the treatment. But in group A, the frequency of bleeding on probing was 36.4%. In these cases, there may still be inflammation in the periodontal pocket after the treatment. This symptom suggests that debridement of the fracture site was inadequate, or that the sealing in the intra-oral bonding method failed because of blood and suppuration at the fracture sites. The retention of microbial dental plaque in these difficult-to-clean areas has been shown to be associated with local periodontal inflammation and periodontal destruction (17–19). Therefore, the intra-oral bonding method might be only effective for fresh fractures and for fractures with little periodontal inflammation. In group B, the sites of bleeding on probing almost disappeared. In the extra-oral method, the periodontal inflammation may have decreased more, since debridement and sealing of the fracture sites were reliable.

In groups A and B, the probing depth was significantly shallower after 6 months. Therefore, the bonding treatment using 4-META/MMA-TBB resin was effective for the improvement of the probing depth. But the deep periodontal pockets, more than 6 mm in 2 of 11 cases of group A and in 6 of 12 cases of group B, remained. The reason for these remaining pockets might be that the periodontal ligament around the fracture line was destroyed or reattachment had not occurred by replantation. Deep periodontal pockets do not necessarily indicate imminent deterioration, and the sites with deep probing depths may be maintained by a periodical recall system for professional cleaning (20). Therefore, the vertically fractured tooth treated by 4-META/MMA-TBB resin with residual pockets may be maintained successfully for a long period by personal plaque control and professional maintenance.

In group B, ankylosis and root resorption were not detected for a mean period of 22 months. The survival of periodontal ligament cells along the root surface is important for periodontal healing (21, 22). Therefore, the segments were soaked with saline for an extended period to maintain the viability of periodontal ligament cells (21, 22). In addition, the bonding of the segments extra-orally may not damage the periodontal ligament cells. Ankylosis was usually diagnosed within the first 2 years after replantation (22). As ankylosis was not detected for a mean period of 22 months in group B, a good long-term prognosis might be expected. However, as the ankylosis could

Table 2. Clinical assessment before and 6 months after the bonding treatment

	Group A (n=11)	Group B (n=12)
Probing depth (mm)		
Pre-treatment	6.55±2.58	7.42±2.50
Re-examination	4.36±2.06**	4.58±2.02**
Bleeding on probing (%)		
Pre-treatment	100	91.7
Re-examination	36.4†	18.3†
Mobility		
Pre-treatment	0.55±0.82	1.27±1.01
Re-examination	0.18±0.60	0.33±0.89
Bone level (%)		
Pre-treatment	56.8±30.0	18.8±30.4
Re-examination	59.1±20.2	29.2±31.7*

The values are expressed as means±S.D

Significant difference between pre-treatment and re-examination: * $P<0.05$ (Wilcoxon signed-rank test); ** $P<0.01$ (Wilcoxon signed-rank test); † $P<0.01$ (Chi-square test).

Table 3. Prognosis of the treated teeth

	Group A (n=11)	Group B (n=12)
Prognosis	Good: 9 (mean>33months)	Good: 9 (mean>22months)
	Extraction: 2	Extraction: 3
	Due to	Due to
	Deep pocket and bone loss (6 months)	Deep pocket and mobility (6 months)
	Refracture (11 months)	Refracture (28 & 29 months)

be diagnosed after 5 and 10 years in rare cases (22), the teeth in group B may need to be monitored carefully for a long period.

As the bone repair was insufficient and the frequency of deep periodontal pocket remained high in both the groups, further examination will be necessary to establish a treatment method for vertical root fracture with advanced periodontal destruction. These bonding treatment methods for vertical root fracture might be more effective in combination with the regenerative therapy using GTR (23) and enamel matrix derivative (24).

References

1. Pitts DL, Natkin E. Diagnosis and treatment of vertical root fractures. *J Endod* 1983;9:338–46.
2. Andreasen JO. Treatment of fractured and avulsed teeth. *J Dent Child* 1971;38:29–31.
3. Schetriit A, Steffensen B. Diagnosis and management of vertical root fracture. *J Can Dent Assoc* 1995;61:607–13.
4. Oliet S. Treating vertical root fractures. *J Endod* 1984;10:391–6.
5. Trope M, Rosenberg ES. Multidisciplinary approach to the repair of vertically fractured teeth. *J Endod* 1992;9:460–3.
6. Selden HS. Repair of incomplete vertical root fractures in endodontically treated teeth-*in vivo* trials. *J Endod* 1996;22:426–9.
7. Masaka N. Long-term observation of fractured tooth roots preserved by adhesion. *Adhesion Dent* 1995;13:156–70.
8. Miller SC. Textbook of periodontia. Philadelphia: Blakiston; 1938.
9. Andersson L, Blomlof L, Lindskog S, Feiglin B, Hammarstrom L. Tooth ankylosis. Clinical, radiographic and histological assessments. *Int J Oral Surg* 1984;13:423–31.
10. Takatsu T, Sano H, Burrow MF. Treatment and prognosis of a vertically fractured maxillary molar with widely separated segments: a case report. *Quintessence Int* 1995;26:479–84.
11. Yokoyama K, Matsumoto K, Kinoshita J, Sasaki H, Komori T. Treatment of maxillary molars with vertical fractures. *Endod Dent Traumatol* 1998;14:287–9.

12. Funato A, Funato H, Matsumoto K. Treatment of a vertical root fracture. *Endod Dent Traumatol* 1999;15:46–7.
13. Miles DA, Anderson RW, Pashley DH. Evaluation of the bond strengths of dentin bonding agents used to seal resected root apices. *J Endod* 1994;20:538–41.
14. Noguchi H, Sugaya T, Kato H. Treatment of vertically fractured root by cohesion. 1. Evaluations of cytotoxicity of adhesive resin cement with cultured periodontal ligament cells. *Jpn J Conserv Dent* 1997;40:1445–52.
15. Noguchi H, Sugaya T, Kato H. Treatment of vertically fractured root by cohesion. 2. Histological evaluations on cohesion with adhesive resin cement and replantation. *Jpn J Conserv Dent* 1997;40:1453–60.
16. Maeda H, Hashiguchi I, Nakamuta H, Toriya Y, Wada N, Akamine A. Histological study of periapical tissue healing in the rat molar after retrofilling with various materials. *J Endod* 1999;25:38–42.
17. Kogon SL. The prevalence, location and conformation of palato-radicular grooves in maxillary incisors. *J Periodontol* 1986;57:231–4.
18. Withers JA, Brunsvold MA, Killoy WJ, Rahe AJ. The relationship of palato-gingival grooves to localized periodontal disease. *J Periodontol* 1981;52:41–4.
19. Hou GL, Tsai CC. Relationship between palato-radicular grooves and localized periodontitis. *J Clin Periodontol* 1993;20:678–82.
20. Badersten A, Nilveus R, Egelberg J. 4 year observations of basic periodontal therapy. *J Clin Periodontol* 1987;4:438–44.
21. Andreasen JO, Andreasen FM. Avulsions. In: Andreasen JO, Andreasen FM, editors. Textbook and color atlas of traumatic injuries to the teeth. 3rd edn. Copenhagen: Munksgaard; 1994. pp. 383–420.
22. Andreasen JO, Borum MK, Jacobsen HL, Andreasen FM. Replantation of 400 avulsed permanent incisors. 4. Factors related to periodontal ligament healing. *Endod Dent Traumatol* 1995;11:76–89.
23. Gottlow J, Nyman S, Lindhe J, Karring T, Wennstrom FM. New attachment formation in the human periodontium by guided tissue regeneration. Case reports. *J Clin Periodontol* 1986;13:604–16.
24. Heijl L. Periodontal regeneration with enamel matrix derivative in one human experimental defect. A case report. *J Clin Periodontol* 1997;24:693–6.