
Periapical resurgery versus periapical surgery: a 5-year longitudinal comparison

M. M. Gagliani, F. G. M. Gorni & L. Strohmenger

Clinica Odontoiatrica, D.M.C.O. San Paolo, School of Dentistry, University of Milan, Milan, Italy

Abstract

Gagliani MM, Gorni, FGM, Strohmenger L. Periapical resurgery versus periapical surgery: a 5-year longitudinal comparison. *International Endodontic Journal*, **38**, 320–327, 2005.

Aim To monitor and compare the outcome of periradicular surgery in teeth that had previously undergone surgical treatment versus teeth that were undergoing a surgical procedure for the first time.

Methodology A total of 164 patients with 231 roots with previously unresolved periapical lesions were followed for up to 5 years following surgery. In all, 162 roots had received unsuccessful conventional root canal treatment (group AS) and 69 had been treated previously using apical surgery (group RS). The surgical procedure was completed using ultrasonic retreatips to prepare the apical root-end cavity, and a zinc-oxide EBA reinforced material was used to fill the apical root-end cavities. Lesions were radiologically examined from 1 to 5 years following the

surgical procedure. Radiographs were independently analysed, according to a previously published classification.

Results In all the roots examined after 5 years, the overall healing rate was 78%; in group AS, 140 (86%) healed with complete bone filling of the surgical cavity, 12 (7%) were considered to have incompletely healed and 10 (6%) were associated with post-treatment disease. In group RS, 41 (59%) healed completely, 12 (17%) were considered to have incompletely healed and 16 (23%) were associated with post-treatment disease. The difference between a second surgical procedure and a first surgical procedure was statistically significant (Mann–Whitney *U*-test, $P = 0.001$).

Conclusion Surgical retreatment of teeth previously treated with surgery is a valid alternative to extraction. However, association with post-treatment disease was greater than after a primary surgical approach.

Keywords: apicectomy, surgical endodontics, ultrasound, endodontics.

Received 5 November 2003; accepted 24 January 2005

Introduction

Surgical endodontics is now a reliable therapeutic procedure for the treatment of teeth with periapical lesions, particularly when orthograde retreatment is problematical (Rud *et al.* 2001, Von Arx *et al.* 2001, Rubinstein & Kim 2002).

Although in the past some conflicting outcomes were reported (Rud *et al.* 1972, Molven *et al.* 1987, Dorn & Gartner 1990, Friedman *et al.* 1991, Frank *et al.*

1992), recent reports have described healing in over 80% of cases following surgery (Sumi *et al.* 1996, Testori *et al.* 1999, Zuolo *et al.* 2000, Von Arx *et al.* 2001, Rubinstein & Kim 2002). The improvement of apical root-end filling materials (Adamo *et al.* 1999) might partially explain the high healing rates achieved by modern surgical techniques (Von Arx *et al.* 1998). In addition, better orthograde treatment choices and case selection might enhance the success of surgical therapies in cases with previous post-treatment disease (Zuolo *et al.* 2000).

There is little information available regarding the outcome of surgical operations performed on teeth that had previously undergone periapical surgery. In a systematic review, Peterson & Gutmann (2001) reported that healing associated with surgical

Correspondence: Prof. Massimo Gagliani, Clinica Odontoiatrica, D.M.C.O. San Paolo, School of Dentistry, University of Milan, Via Beldiletto, 1, 20142 Milan, Italy (Tel.: +39 02 50319012; fax: +39 02 50319040; e-mail: massimo.gagliani@unimi.it).

retreatment was approximately 36%. This compares unfavourably with surgery on teeth previously treated by orthograde techniques alone, where the outcome would reflect healing in over 60% of cases.

Most of the literature available on repeated surgical procedures is over 20 years old (Personn 1973) and includes data from procedures using materials and techniques that are no longer used today. In addition, the literature often includes surgical retreatment on teeth which had not received a root-end filling. Rud *et al.* (1996, 2001) reported on a longitudinal study of teeth treated surgically, including 21 and 25 roots with a healing rate at follow-up of 76 and 80%, respectively.

The purpose of the present paper is to investigate the outcome of surgical endodontic treatment in teeth without previous periapical surgery compared with the outcome of surgical endodontic treatments in teeth that had previously undergone root-end resection.

Materials and methods

Over an 18-month period from June 1995 to December 1996, a total of 268 patients, referred to the Department of Endodontics, D.M.C.O. San Paolo, Milan, for surgical endodontic treatment, were examined for inclusion.

Patient selection and inclusion/exclusion criteria

Of the original total, 232 patients in good general health were admitted to the preliminary evaluation protocol. Clinical and radiographic examinations were performed on each of these patients in order to determine whether the tooth/teeth for which they had requested surgical treatment was/were suitable.

The clinical criteria were:

1. A history of a previous orthograde root canal treatment or a previous surgical treatment with apical root-end filling.
2. No clinical signs or symptoms that could link the lack of healing to periodontal disease or radicular fractures or perforations. Teeth with periodontal probing >6 mm were excluded from the study.

The radiographic inclusion criteria were:

1. Root fillings within 2.5 mm of the radiographic apex and no marked evidence of easily detectable voids inside the root canal.
2. Maximum diameter of the periapical lesion was <10 mm, measured according to the method illustrated by Von Arx *et al.* (2001).

An informed consent form was issued and signed by every participant in the study. At the end of this screening procedure, 194 teeth in 185 patients were included in the study. A total of 264 roots were considered as observation units.

According to preoperative radiographs, the roots were then divided into two groups: group AS for roots that had undergone apical surgery for the first time and group RS for roots that had already undergone a surgical procedure.

The roots were divided into three main categories: anterior (incisors and canine teeth), premolars and molars.

In molar teeth, only the roots affected by periapical pathosis were considered, and underwent a surgical procedure; the outcome for each root was considered separately.

Surgical procedures

All procedures were performed by a single surgeon, using magnification loupes ($\times 4.5$). A sulcular full-thickness flap was used in all cases, with one or two releasing incisions, according to the clinical need. The bone cavity for each root was prepared using round tungsten-carbide burs (H408; Komet, Lemgo, Germany) under copious water cooling. Rinsing with saline solution was provided intermittently during the whole surgical procedure in order to prevent dehydration of bone.

Surgical debridement of the bone tissue was performed with a bur and sharp spoon excavator.

Root apex treatment in group AS

Using a water-cooled tungsten-carbide bur (700xL; Komet, Lemgo, Germany), an apical resection of approximately 3 mm was performed with a limited bevel.

Root apex treatment in group RS

Taking into consideration that the previous operation had reduced the root length in this group of teeth, the new resection was limited in length; the borders of the previous preparation were refined. The original apical filling material was removed and the type of material recorded.

Apical root-end cavity preparation

Root-end preparation was performed by an ultrasonic technique. In molars, only the root(s) involved in the periapical disease were treated.

The tips employed in the different clinical conditions were alternatively: CT1, CT2 and CT3 (Sybron Endo, Orange, CA, USA). The root-end cavities were prepared to a depth of 3 mm.

An ultrasonic unit (PM400; EMS, Nyon, Switzerland) was used at a medium power setting, as suggested in previous reports (Sumi *et al.* 1996, Von Arx *et al.* 1998).

Substantial volumes of water were used and a final saline solution irrigation was performed at the end of the root-end cavity preparation.

A ferric-sulphate solution (Astringedent X; Ultradent, Salt Lake City, UT, USA) was employed to limit bleeding and sterile paper points were used to dry the root-end cavities; the drying process was enhanced by the use of a gentle steam of air (Stropko syringe; Sybron Endo).

A modified zinc-oxide eugenol cement with EBA (Super Seal; Ognia Pharmaceuticals, Milan, Italy) was used as the root-end filling material. No space-making or space-maintenance biomaterials were placed in the wound.

Nonresorbable 4/0 silk (Ethicon Italy, Pomezia, Italy) was used for suturing.

A radiographic and clinical overview of two cases included in the protocol is supplied in Figs 1–7.

Radiographic examination

Radiographic centring

Appropriate film holders (Superbite with centering aids; Kerr Hawe-Neos, Bioggio, Switzerland) and Ultraspeed X-ray film (Eastman Kodak Company, Rochester, NY, USA) were used throughout the study with a parallelizing technique (Delano *et al.* 1998).

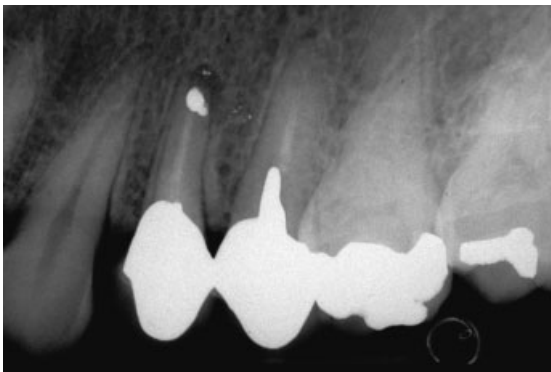


Figure 1 A periapical radiolucency on an upper premolar to be retreated.

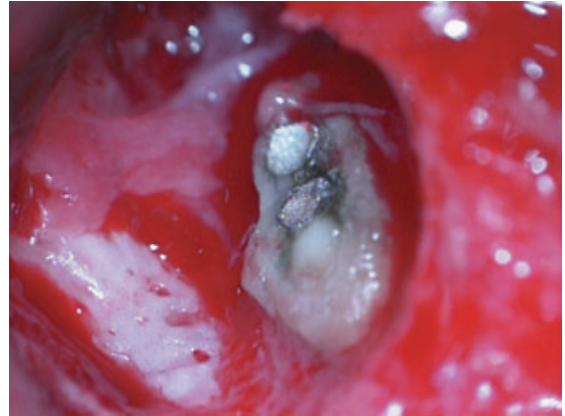


Figure 2 The surgical access to the apex showing an incomplete amalgam seal.

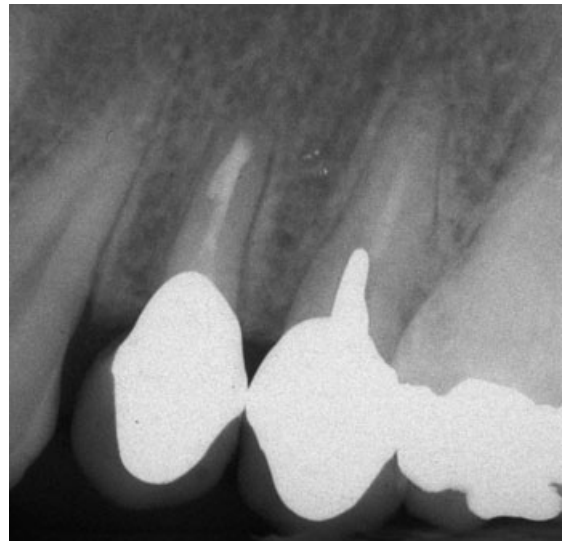


Figure 3 The healing process after 5 years.

Radiographs were taken prior to surgery, after root-end preparation, after root-end filling prior to suturing, and at each follow-up appointment, normally one per year.

Clinical signs and symptoms were recorded at each recall visit.

Evaluation of radiographs

The preoperative radiograph and the final one were evaluated according to the classification based on Rud *et al.* (1972).

Complete healing was assigned for roots showing a complete 'lamina dura' around the apical contour of the roots.

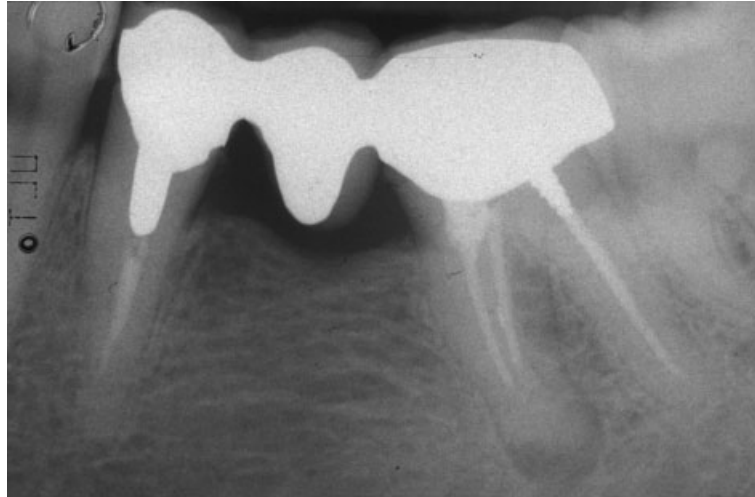


Figure 4 A failure of endodontic origin in a lower molar.

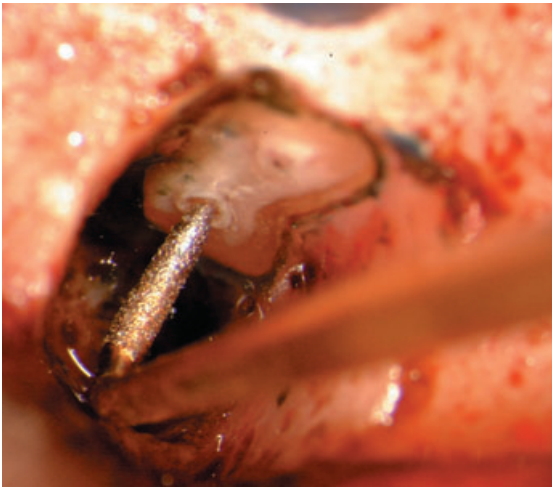


Figure 5 The ultrasonic device and cavity ready to be filled.

Incomplete healing was assigned for roots showing a clear reduction in size of the radiolucency.

Failure was assigned to all roots that did not show any reduction in lesion size. This category also included all those teeth extracted for endodontic reasons.

Two endodontists, unaware of the aims of the study, and with at least 10 years clinical experience evaluated the radiographs. Printed instructions and reference radiographs depicting different periapical conditions – according to the above-mentioned criteria – were provided in order to calibrate the evaluators.

All radiographs were independently examined by each observer under 2× magnification (Patel *et al.* 2000) and assigned to the appropriate category at the corresponding final time. Both observers reviewed approximately 40% of the radiographs 40 days after

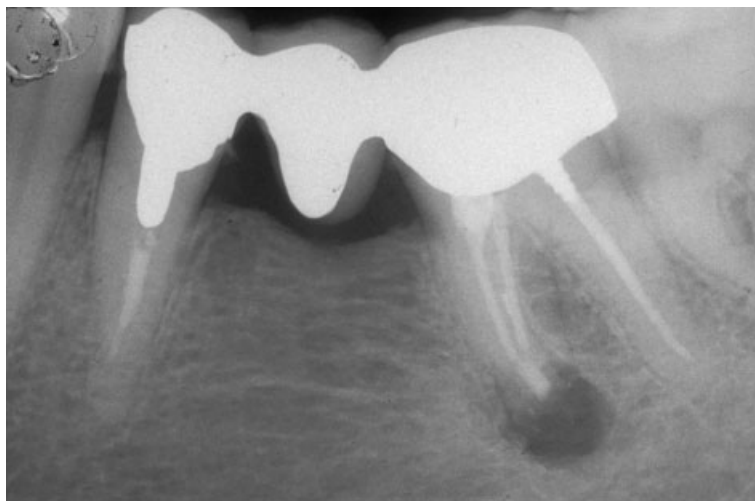


Figure 6 The radiographic appearance just after surgery.

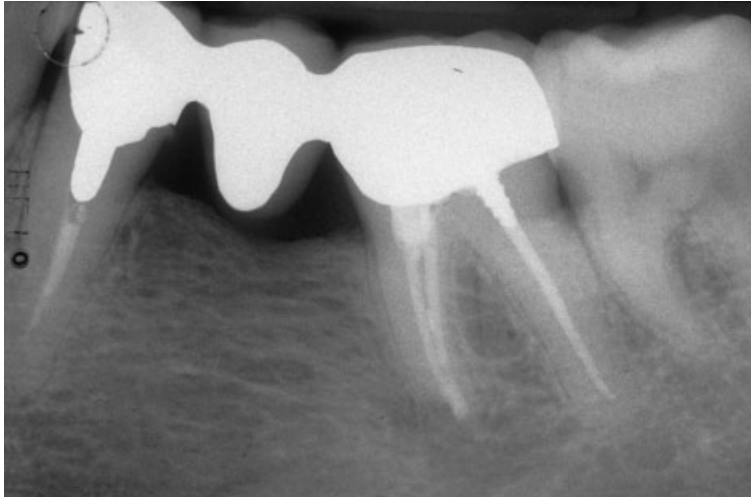


Figure 7 The radiographic appearance after 5 years.

the first evaluation. In cases of inter-observer disagreement the worst result was accepted.

Clinical records

For the final analyses, the radiographic classification was integrated – independently from the observers – with the clinical records, to give the appropriate evaluation to each case. Clinical signs, such as sinus tracts or symptoms, or tenderness to percussion, were taken to indicate failure. Radiographic improvements of the lesion associated with clinical signs or symptoms were assigned to the failure category.

Statistical analysis

A complete descriptive assessment of the results was performed using percentage and confidence interval (CI). Nonparametric tests were used for the main outcome evaluations (Mann–Whitney *U*-test, $P < 0.05$).

Differences in outcomes for roots of anterior, premolar and molar teeth were confirmed by Kruskal–Wallis test.

Reproducibility of evaluators

Inter- and intra-observer analyses were performed using Cohen's κ statistics (Brunette 1996).

Results

Twenty-one of the 185 patients enrolled in the study did not attend the recall (Table 1); two of them had

Table 1 Patients enrolled in the study after the first clinical visit: 36 were excluded because of systemic disease. Patients with vertical root fractures or perforations diagnosed before surgery or roots with clearly insufficient canal obturation were not eligible.

	Total	M	F
Admitted to visit	268	131	137
Excluded by systemic disease	36	20	16
Examined	232	111	121
Not eligible	47	21	26
Enrolled	185	90	95
Lost follow-up	21	12	9
Followed up	164	78	86
Mean age (years)	41.8	41.7	41.9
SD	12.9	13.4	11.8
Range	18–72	18–72	23–66

changed address, one had died, seven were not able to attend the final examination in time and 11 of them did not consent to the radiographic and clinical follow-up appointment.

A total of 168 teeth with 231 roots in 164 patients were thus considered.

In virtually all the retreatment cases, the previous root-end filling material was amalgam. Only two had zinc-oxide eugenol cement and five had only an apical resection without a root-end filling material.

Of the 231 roots examined after 5 years, 78% had completely healed, 10% had incompletely healed and 11% were associated with post-treatment disease. Further analyses of the results (Table 2) indicated complete healing in 86% of the AS group and 59% of the RS group. The difference in proportion for complete healing was 27% (95% CI 15–40%), whilst for failures it

Table 2 Final results of the whole sample and split into the two groups AS (teeth at the first apical surgery) and RS (teeth already treated by apical surgery). The outcome were different and statistically significant (Mann–Whitney *U*-test, $P = 0.0015$)

	Teeth (<i>n</i>)	Roots (<i>n</i>)	Outcome			Statistical analyses
			Complete	Incomplete	Failure	
General	168	231	181 (78.4)	24 (10.4)	26 (11.2)	Mann–Whitney, $P < 0.001$
Group AS	114	162	140 (86.4)	12 (7.4)	10 (6.4)	
Group RS	54	69	41 (59.4)	12 (17.4)	16 (23.2)	
Group AS						
Anterior	13	13	12 (92.3)	0 (0.0)	1 (7.7)	Kruskal–Wallis, $P = 0.28$
Premolar	41	41	38 (92.7)	2 (4.9)	1 (2.4)	
Molar	60	108	90 (83.3)	10 (9.3)	8 (7.4)	
Group RS						
Anterior	15	15	7 (46.7)	1 (6.6)	7 (46.7)	Kruskal–Wallis, $P = 0.18$
Premolar	15	15	11 (73.3)	2 (13.4)	2 (13.3)	
Molar	24	39	23 (59.0)	9 (23.1)	7 (17.9)	

was 17% (95% CI 7–29%). This difference was statistically significant (Mann–Whitney *U*-test, $P = 0.001$).

The percentage of complete healing was high in premolar roots of the AS group (93%) followed by anterior roots (92%) and molar roots (83%).

A low percentage of healing (47%) was observed in the anterior teeth from the RS group. In this group, complete healing was observed in 73% of premolars and in 59% of molars. No statistically significant difference was observed between roots of anterior, premolar and molar teeth within each treatment category.

Functional teeth/roots, including complete and incomplete healing, was 89%: in the AS group it was 94% and in the RS group it was 77%.

The ability to reproduce radiographic observations, made by κ statistics, for intra-observers was 0.76 for one observer and 0.71 for the other; for inter-observer validity it was 0.79.

Discussion

The aim of the present study was to compare the outcome in cases of first time endodontic surgery with cases in which apical surgery was being repeated. A further objective of this study was to evaluate whether more recent surgical techniques might offer better opportunities in the outcome of such cases. The choice of focusing on roots not teeth reflected that of a previous study (Rud *et al.* 2001). This might lead to a more optimistic final result but in several cases involving molars, this data was useful, for example, in verifying the behaviour of a single root-end affected by a periapical lesion and therefore subject to treatment or retreatment. Amongst the case histories examined, a large percentage of molar root-ends were included. This

could be due to the fact that patients had been treated initially in a specialist centre specifically dedicated to endodontic surgery.

The use of a single operator might be one of the drawback of this study; in addition, the skill of the operator and the working conditions, such as magnification and a carefully standardized working procedure might positively affect the final outcome.

The influence of the operator was confirmed by Rahbaran *et al.* (2001) who reported that operators of different experience and equipment adversely affected the outcome.

The study considered both roots that had already undergone periapical surgery and roots assigned to endodontic surgery for the first time: in order to make the two groups homogeneous, the choice was made to exclude patients with systemic health problems. Moreover, roots with clearly deficient root fillings were excluded to eliminate additional confounding variables. The number of patients lost during the follow-up could be considered normal and indeed lower in comparison with other similar studies.

Another element that may lead to a more optimistic evaluation of all the cases is the type of analyses conducted on radiographs. The categories were similar to those adopted in previous studies (Rud *et al.* 1972) and make the results of this study more comparable. More strict and detailed criteria were proposed by Orstavik *et al.* (1986) but this method was considered unsuitable for periapical surgery (Chong *et al.* 2003). The calibration of the observers and radiographic analyses were similar to those reported by Delano *et al.* (1998), and the reliability of the two observers was good.

From the analysis of the data, the healing associated with anterior teeth in the RS group was interesting.

The percentage of disease was not comparable to that found in all the other groups of teeth examined in this study. However, a possible explanation can be given. The size of the root-end cavity in these roots was larger and therefore more difficult to completely fill when compared with that done on other root types.

The results of initial surgery on roots can be compared to existing case histories. Studies on the outcome of periapical surgery have reported varied results with healing rates ranging from 30 to 95% (Rud *et al.* 1972, Dorn & Gartner 1990, Friedman *et al.* 1991, Frank *et al.* 1992, Sumi *et al.* 1996, Rubinstein & Kim 1999). However, these studies differed in sample size, type of teeth, surgical technique, type of root-end filling material and radiographic evaluation criteria.

Few articles deal directly with periapical resurgery. The recent meta-analysis by Peterson & Gutmann (2001) reported a low healing rate for teeth undergoing repeat surgery. Furthermore, amongst the eight studies included in the analysis, six of them had been performed prior to the 1980s, in an era when surgical techniques and materials were mostly different than today.

A study that included an adequate number of teeth previously treated using surgical techniques was reported by Personn (1973). In that study, healing occurred in 38% of cases compared to the 59% in the present study. However, the techniques and materials reported here are different and are likely to explain the discrepancy. A more realistic comparison could be made with the studies of Rud *et al.* (1996, 2001). These reported a general healing rate of 76 and 80%, respectively. The data reported here are inferior to these results but the cases in the present study were monitored over a longer time-period of 5 years. In addition, teeth in previous studies had already been treated surgically by the same operators.

In the present study repeat root-end surgery had a worse radiological outcome compared with primary root surgery. Such a finding differs from that reported by Rahbaran *et al.* (2001); however, the surgical protocols were different and the number of teeth was low. There is evidence that modern surgical endodontic techniques and filling materials can improve the outcome of teeth undergoing endodontic surgery (Dorn & Gartner 1990, Testori *et al.* 1999). Recent studies report an overall percentage of favourable outcome >90% (Rud *et al.* 2001, Von Arx *et al.* 2001, Chong *et al.* 2003, Maddaloni & Gagliani 2003). In this study, a similar rate of favourable outcome was observed in the primary periapical surgery group. The second

surgical intervention group showed a percentage of favourable outcome lower but still valuable if compared to success rates previously reported in the literature.

Conclusion

The outcome of repeat endodontic surgery was less favourable than that of primary endodontic surgery for post-treatment disease.

References

- Adamo HL, Buruiana R, Schertzer L, Boylan RJ (1999) A comparison of MTA, Super-EBA, composite and amalgam as root-end filling materials using a bacterial microleakage model. *International Endodontic Journal* **32**, 197–203.
- Brunette DM (1996) *Critical Thinking: Understanding and Evaluating Dental Research*. Chicago, IL: Quintessence Publishing Co.
- Chong BS, Pitt Ford TR & Hudson MB (2003) A prospective clinical study of Mineral Trioxide Aggregate and IRM when used as root-end filling materials in endodontic surgery. *International Endodontic Journal* **36**, 520–6.
- Delano EO, Tyndall D, Ludlow JB, Trope M, Lost C (1998) Quantitative radiographic follow-up of apical surgery: a radiometric and histologic correlation. *Journal of Endodontics* **24**, 420–6.
- Dorn SO, Gartner AH (1990) Retrograde filling materials: a retrospective success-failure study of amalgam, EBA, and IRM. *Journal of Endodontics* **16**, 391–3.
- Frank AL, Glick DH, Patterson SS, Weine FS (1992) Long-term evaluation of surgically placed amalgam fillings. *Journal of Endodontics* **18**, 391–8.
- Friedman S, Lustmann J, Shaharabany V (1991) Treatment results of apical surgery in premolar and molar teeth. *Journal of Endodontics* **17**, 30–3.
- Maddaloni M, Gagliani M (2003) Periapical endodontic surgery: a 3-year follow-up study. *International Endodontic Journal* **36**, 193–8.
- Molven O, Halse A, Grung B (1987) Observer strategy and the radiographic classification of healing after endodontic surgery. *International Journal of Oral Maxillofacial Surgery* **16**, 432–9.
- Orstavik D, Kerekes K, Eriksen HM (1986) The periapical index: a scoring system for radiographic assessment of apical periodontitis. *Endodontics and Dental Traumatology* **2**, 29–34.
- Patel N, Rushton VE, Mac Farlane TV, Horner K (2000) The influence of viewing conditions on radiological diagnosis of periapical inflammation. *British Dental Journal*, **189**, 40–2.
- Personn G (1973) Prognosis of reoperation after apicoectomy. *Swedish Dental Journal* **66**, 49–67.
- Peterson J, Gutmann JL (2001) The outcome of endodontic resurgery: a systematic review. *International Endodontic Journal* **34**, 169–75.

- Rahbaran S, Gilthorpe M, Harrison S, Gulabivala K (2001) Comparison of clinical outcome of periapical surgery in endodontic and oral surgery units of a teaching dental hospital: a retrospective study. *Oral Surgery, Oral Medicine, Oral Pathology, Oral Radiology and Endodontics* **91**, 700–9.
- Rubinstein R, Kim S (1999) Short term observation of the results of endodontic surgery with the use of a operation microscope and Super-Eba as root-end filling material. *Journal of Endodontics* **25**, 43–8.
- Rubinstein RA, Kim S (2002) Long-term follow-up of cases considered healed 1 year after apical microsurgery. *Journal of Endodontics* **28**, 378–83.
- Rud J, Andreasen J, Moller Jensen J (1972) A follow-up study of 1000 cases treated by endodontic surgery. *International Journal of Oral Surgery* **1**, 215–28.
- Rud J, Rud V, Munksgaard EC (1996) Long-term evaluation of retrograde root filling with dentin-bonded resin composite. *Journal of Endodontics* **22**, 90–3.
- Rud J, Rud V, Munksgaard EC (2001) Periapical healing of mandibular molars after root-end sealing with dentine-bonded composite. *International Endodontic Journal* **34**, 285–92.
- Sumi Y, Hattori H, Hayashi K, Ueda M (1996) Ultrasonic root-end preparation: clinical and radiographic evaluation of results. *Journal of Oral and Maxillofacial Surgery* **54**, 590–3.
- Testori T, Capelli M, Milani S, Weinstein RL (1999) Success and failure in periradicular surgery: a longitudinal retrospective analysis. *Oral Surgery, Oral Medicine, Oral Pathology, Oral Radiology and Endodontics* **87**, 493–8.
- Von Arx T, Kurt B, Ilgenstein B, Hardt N (1998) Preliminary results and analysis of a new set of sonic instruments for root-end cavity preparation. *International Endodontic Journal* **31**, 32–8.
- Von Arx T, Gerber C, Hardt N (2001) Periradicular surgery of molars: a prospective clinical study with a one-year follow-up. *International Endodontic Journal* **34**, 520–5.
- Zuolo ML, Ferreira MO, Gutmann JL (2000) Prognosis in periradicular surgery: a clinical prospective study. *International Endodontic Journal* **33**, 91–8.