

# Submergence of roots for alveolar bone preservation

## I. Endodontically treated roots

*Robert B. O'Neal, Major, DC, USA,\* Tom Gound, Major, USAF (DC),\*\* Marvin P. Levin, Colonel, DC, USA,\*\*\* and Carlos E. del Rio, Colonel, DC, USA\*\*\*\**

UNITED STATES ARMY INSTITUTE OF DENTAL RESEARCH, WALTER REED ARMY MEDICAL CENTER, WASHINGTON, D. C.

Mandibular premolars in four mongrel dogs were endodontically treated, sectioned, reduced in situ so that each root was approximately 2 mm. below the alveolus, and totally submerged. Histologic and radiographic findings showed that this procedure should be used to preserve alveolar bone.

The alveolar ridge is resorbed following tooth extraction, whether or not it supports a prosthesis.<sup>1</sup> Maintaining the alveolar ridge of complete-denture patients has been a continuing major problem in dentistry and has stimulated research on the feasibility of retaining roots as a means of conserving the ridge.<sup>2</sup>

Total submergence of tooth roots has been advocated in cases of advanced periodontal disease with considerable bone destruction, particularly for mandibular anterior teeth where no posterior teeth remain.<sup>3</sup>

In the submergence procedure the crown is sectioned from the root at or below the level of the alveolar bone, and the residual root is covered with a flap. Four methods of treating the remaining root have been reported in the literature: (1) vitality is preserved in

---

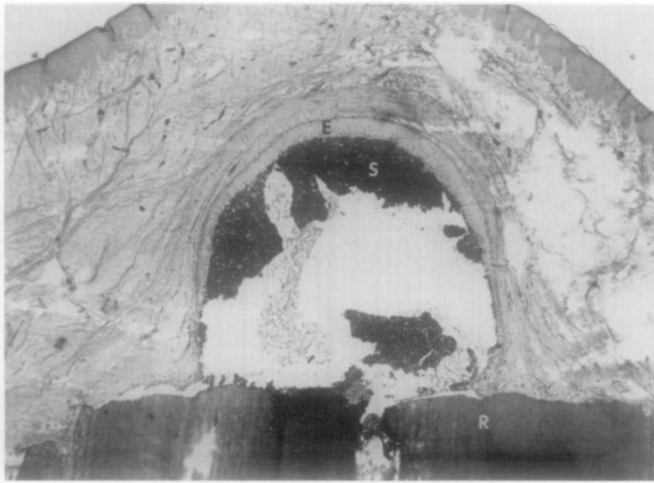
In conducting research described in this report, the investigators adhered to the *Guide for the Care and Use of Laboratory Animals*, as promulgated by the Committee on the Revision of the Guide for Laboratory Animal Facilities and Care of the Institute of Laboratory Animal Resources, National Research Council.

\*Periodontic Resident.

\*\*Endodontic Resident.

\*\*\*Chief, Department of Clinical Specialties; Director, Periodontic Residency.

\*\*\*\*Formerly Chief, Division of Clinical Research; Director, Endodontic Residency; at present, Associate Professor of Endodontics, The University of Texas Health Science Center at San Antonio.



**Fig. 1.** Epithelium-lined cyst (*E*) in a 90-day specimen associated with the coronal portion of the root (*R*). The cyst is filled with root canal sealer (*S*). ( $\times 40$ .)

the residual root and submerged,<sup>4-6</sup> (2) pulpectomy is performed in the residual root and submerged without root canal therapy,<sup>7</sup> (3) the residual root segment is treated endodontically and submerged,<sup>8</sup> (4) the endodontically treated root segment is intentionally replated and submerged.<sup>9</sup> The most widely used method is to complete endodontic treatment prior to submerging the root.

The purpose of the present study is to investigate the biologic response to roots that are endodontically treated and then submerged.

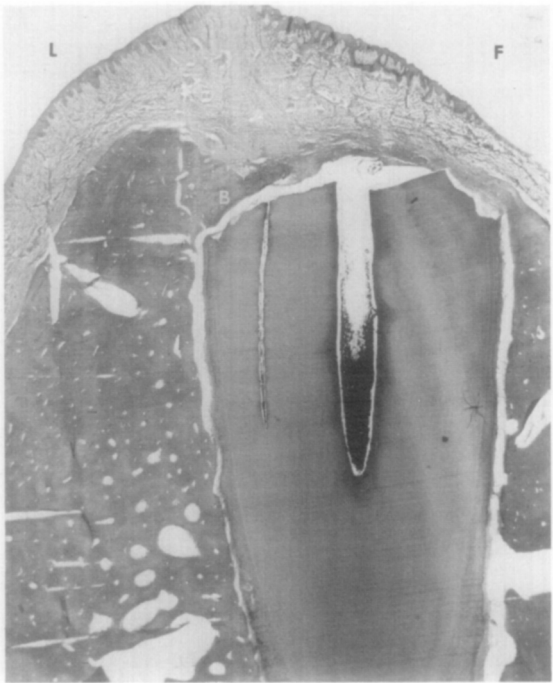
## **MATERIALS AND METHODS**

Four healthy mongrel dogs were used. Their ages ranged from 2 to 5 years, and they weighed approximately 40 pounds. The dogs were premedicated with Innovar, 1 c.c. per 20 pounds of body weight. The operation was performed under general anesthesia with Pentothal sodium, 1 c.c. per 50 pounds of body weight, and nitrous oxide, 50 per cent concentration.


The four mandibular premolars were used in this study, with the single-rooted first premolars serving as controls; sixteen roots of the remaining premolar teeth were selected at random to be used in this study. Both the control and the experimental teeth were treated endodontically. Following conventional preparation, the canals and pulp chambers were filled with gutta-percha by the lateral condensation technique. Kerr Tubli-Seal\* cement was used as the sealer.

A local anesthetic (lidocaine 2 per cent with 1/100,000 epinephrine) was administered for hemorrhage control. Full-thickness mucoperiosteal flaps were reflected on the buccal and lingual aspects of the mandible. Inverse bevel incisions were used so that creviclec-tomy could be accomplished. All excess soft tissue around the teeth was removed with curets. The first premolars received no treatment other than reflection of the flap.

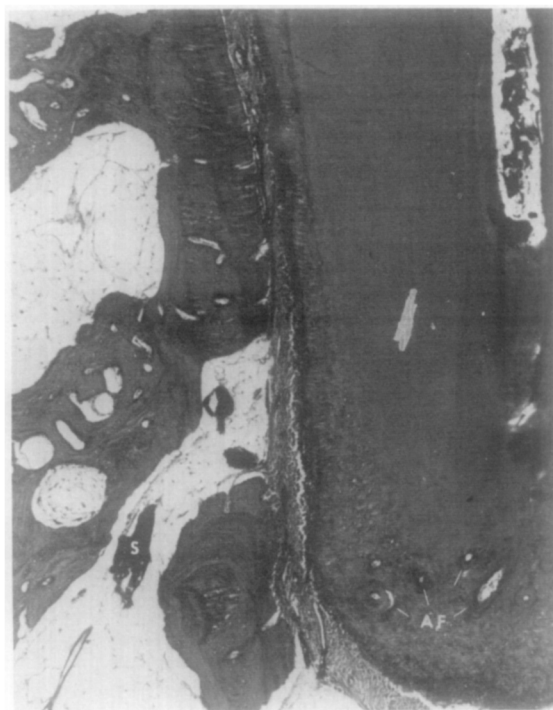
\*Kerr Sybron Corp., Romulus, Mich.



**Fig. 2.** Specimen at 90 days with partial bone formation (*B*) coronal to the root. Bone formation on the lingual (*L*) is higher than on the facial (*F*) aspect, which was characteristic of all specimens sectioned buccolingually. ( $\times 10$ .)



**Fig. 3.** Photomicrograph of a 120-day specimen without coronal bone. Particles of the root canal sealer (*S*) are present with minimal inflammatory infiltrate and new cementum (*arrow*) is separated by artifact. ( $\times 40$ .)



**Fig. 4.** Multiple apical foramina (AF) common in canine premolars and root canal sealer (S) in the marrow space. ( $\times 40$ .)

**Table I.** New bone formation over endodontic submerged roots\*

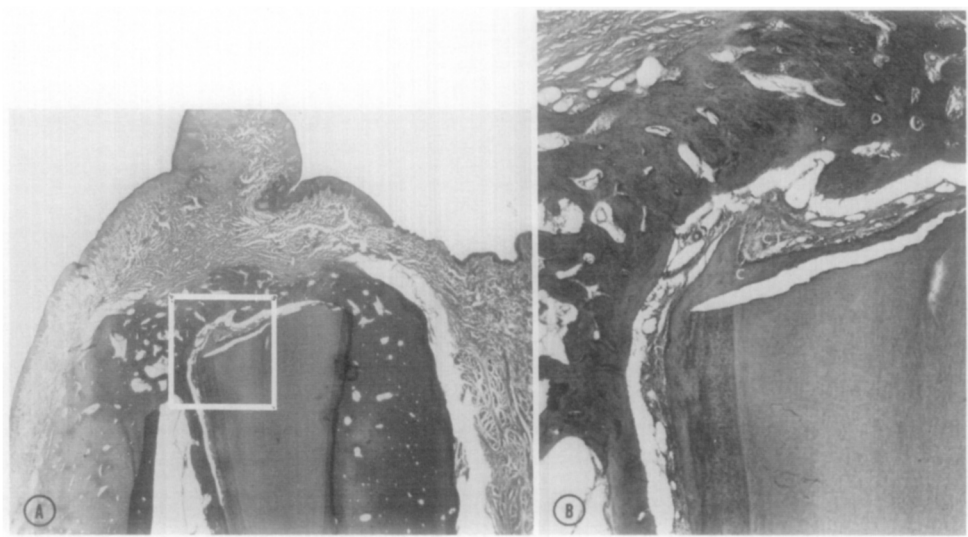
New bone	Scale			
	0	1	2	3
16 roots	4	2	3	7

\*Twelve showed coronal apposition.

The endodontically treated experimental teeth were sectioned and reduced in the mouth so that each root was approximately 2 mm. below the alveolus. This was accomplished with a diamond bur and water spray as a coolant.

Releasing incisions were made in the periosteum at the base of the buccal flap. Primary closure was achieved with a mattress suture technique. Each animal received 600,000 units of benzathine penicillin G suspension and 600,000 units of procaine penicillin G immediately after the procedure. Sutures were removed 7 days postoperatively.

The animals were killed in a sequence that provided two specimens and a control at the following postoperative times: 30, 40, 45, 55, 60, 90, and 120 days. This was done to determine the repair activity coronal to the submerged roots. Heparin was administered 30 minutes prior to each killing. Under general anesthesia the animals were killed by perfusion with 4 L. of a 10 per cent buffered solution of formalin through a cannula in the aorta. The mandible was removed en bloc and sectioned with one root per section. The sections



**Fig. 5.** A, A specimen at 60 days demonstrating complete bone formation over the coronal root surface. ( $\times 10$ .) B, Higher magnification ( $\times 40$ ) of A, showing new cementum (C) and connective tissue (CT) continuous with the periodontal ligament separating the coronal dentin and new bone formation.

**Table II.** Inflammation with endodontic submerged roots

	Scale			
	0	1	2	3
Periapical	15	0	1	0
Pericoronal	7	3	3	3 (3 cysts)

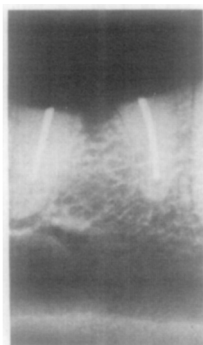
were fixed in 10 per cent buffered formalin, decalcified, embedded in paraffin, sectioned at 7 to 10  $\mu$ , and then stained with hematoxylin and eosin for histologic study. Where possible, in preparation of the histologic slides, the roots of the teeth were oriented so that a mesiodistal section of one root and a buccolingual section of the other root of the same tooth were obtained.

The resulting slides were graded for inflammation coronal to the root segment and in the periapical area according to the following scale: 0, no evidence of inflammation; 1, minimal reaction, characterized by a diffuse scattering of inflammatory cells in a prescribed area; 2, moderate reaction—amixed inflammatory infiltrate, not well localized; 3, severe reaction characterized by a heavy infiltration, possibly accompanied by resorption of bone.

Bone regeneration coronal to root segment was graded as follows: 0, no evidence of regeneration; 1, minimal bone regeneration; 2, bone regeneration covering at least half the root segment; 3, bone regeneration covering the entire root segment.

**RESULTS**

Primary closure of the flap resulted in rapid healing of all surgical sites, and there was no evidence that the gingiva was perforated by a root segment in any of the specimens.



**Fig. 6.** Lateral radiograph of submerged root in Fig. 2. Radiographic examination shows no coronal bone formation.

Clinically, the ridge contours were normal with two exceptions. In these two specimens the gingiva was slightly elevated. This occurred in a 45-day and a 90-day specimen. Histologic evaluation revealed cystic areas associated with coronal portions of the roots. These epithelium-lined cysts prevented the formation of osteocementum over the coronal surface. In this study the origin of the epithelium was not determined (Fig. 1).

None of the experimental roots exhibited resorption. The inflammation associated with the endodontically treated roots appeared to be primarily a response to the excess root canal sealer that was expressed coronally and periapically (Fig. 4). Inflammation was evident in all specimens up to 90 days (Fig. 2), but the inflammatory infiltrate was minimal in the 120-day specimens (Fig. 3). The cellular reaction was predominantly a chronic inflammatory response which had walled off the excess root canal sealer. The scores for inflammation and coronal apposition are shown in Tables I and II. New bone formation which extended over more than half of the coronal surface was observed in 62.5 per cent of the submerged roots despite the presence of the root canal sealer. The 60-day specimens demonstrated the first complete bone coverage (Fig. 5). This specimen is also representative of the formation of a new osteocementum and connective tissue layer separating the coronal dentin from the new bone formation.

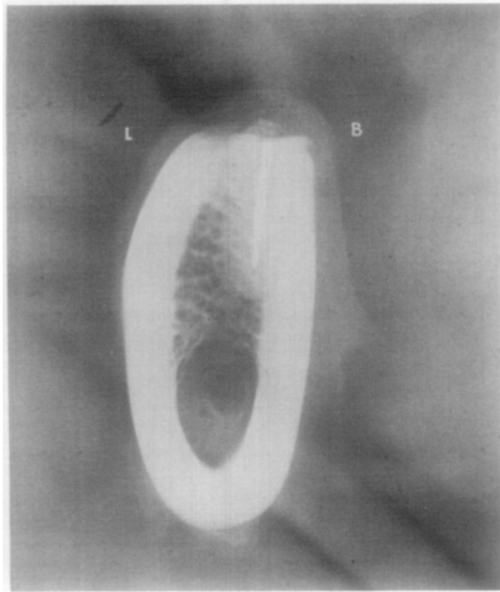
None of the control teeth exhibited root resorption or radicular inflammation. Lateral radiographs (Fig. 6) did not reveal new alveolar bone over the roots, but mesiodistal radiographs (Fig. 7) showed the beginning of ossification coronal to the root segment and new bone was readily observable on histologic examination.

## DISCUSSION

Dogs were selected for the present study because of their physiologic similarity to human subjects and the comparable reactivity of the periodontal structures.<sup>10</sup> Although the experimental time periods were relatively short, Dixon and Rickert<sup>11</sup> have noted that bony healing occurs  $2\frac{1}{2}$  to 3 times more rapidly in dogs than in man.

Performing the endodontic procedures and submerging the root at the same time allowed the sealer to express from the coronal portion of the root. At the time of flap closure there was no evidence of sealer on the coronal portion of the root. The elastic rebound from lateral condensation apparently caused the material to be expressed some time after the procedure had been completed.

The inflammation surrounding the root canal sealer could have been eliminated by



**Fig. 7.** Mesiodistal radiograph showing the relative position of the root in relation to the buccal (*B*) and lingual (*L*) cortical plates.

placing an amalgam filling in the canal orifice or by staging the procedure in two steps to allow the sealer to harden. However, in spite of the presence of inflammation, new bone formed coronal to the root in some cases (Fig. 2).

From buccolingual microscopic sections, it was noted that the lingual alveolar bone was more coronal than the buccal in relationship to the submerged root. It was apparent during the surgical procedure that the radicular bone over the buccal surface was very thin. This accounts for the radiographic appearance of the alveolar crest (Fig. 7). In future experiments it may be advisable to bevel the root segment toward the buccal surface to avoid perforation under function. This may explain the perforation which Simon and Kimura<sup>9</sup> reported on the distal buccal area in several of their clinical cases.

As a result of this study, it appears that submergence of roots for preservation of the alveolar ridge has great potential. However, a periodic postoperative radiographic follow-up is indicated to rule out pathosis, such as cysts.

## **SUMMARY**

Mandibular premolars in four dogs were endodontically treated and then totally submerged. Histologic and radiographic findings showed that this procedure should be considered as an alternative to extraction of key teeth in an effort to preserve alveolar bone.

1. Periodic follow-up on this procedure should be done to rule out cystic formation.
2. Beveling of the coronal portion to the buccal is advocated to compensate for the thin buccal plate.
3. The procedure should be done in two steps to allow the root canal sealer to set, or an amalgam should be placed over the pulp canal.
4. New cementum and connective tissue will form over the coronal surface separating the dentin from new bone.

**REFERENCES**

1. Lam, R.: Contour Changes of the Alveolar Process Following Extractions, *J. Prosthet. Dent.* **22**: 25-32, 1960.
2. Goska, F., and Vandrak, R.: Roots Submerged to Preserve Alveolar Bone: A Case Report, *Mil. Med.* **137**: 446-447, 1972.
3. Sander, A.: Endodontics and the Full Denture, Transactions of the Fifth International Conference of Endodontics, Philadelphia, pp. 16-27, 1973.
4. Poe, G., Hillenbrand, D., and Johnson, D.: Vital Root Retention in Dogs, Technical Report 019, Naval Graduate School, Bethesda, Md., July, 1971.
5. Whitaker, D., and Shankle, R.: A Study of the Histological Reaction of Submerged Root Segments, *ORAL SURG.* **37**: 919-935, 1974.
6. Johnson, D., Kelly, J., Flinton, R., and Cornell, M.: Histologic Evaluation of Vital Root Retention, *J. Oral Surg.* **32**: 829-833, 1974.
7. Levin, M., Getter, L., Cutright, D., and Bhaskar, S.: Intentional Submergence of Nonvital Roots, *J. Oral Surg.* **32**: 834-839, 1974.
8. Reames, R., Nickle, J., Patterson, S., Boone, M., and El-Kafrawy, A.: Clinical Radiographic and Histologic Study of Endodontically Treated Retained Roots to Preserve Alveolar Bone, *J. Endo.* **1**: 367-372, 1975.
9. Simon, J., and Kimura, J.: Maintenance of Alveolar Bone by the Intentional Reimplantation of Roots, *ORAL SURG.* **37**: 936-944, 1974.
10. Grossman, L.: Intentional Replantation of Teeth, *J. Am. Dent. Assoc.* **72**: 1111-1118, 1966.
11. Dixon, C. M., and Rickert, U. G.: Histologic Verification of Results of Root Canal Therapy in Experimental Animals, *J. Am. Dent. Assoc.* 1781-1803, 1938.

*Reprint requests to:*

Dr. Carlos E. del Rio  
The University of Texas Dental School  
7703 Floyd Curl Dr.  
San Antonio, Texas 78284

**ERRATUM**

In the article entitled "Endodontic Morphology" by R. W. Hession, which appeared serially in the September through December, 1977, issues of the JOURNAL, the illustrations designated Fig. 7 were transposed in the third and fourth installments. In other words, the roentgenogram which appeared above the legend for Fig. 7 on page 781 of the November issue should have been published above the legend for Fig. 7 on page 923 of the December issue, and the illustration shown as Fig. 7 in the December issue should have appeared on page 781 of the November issue.