

Histological Appearance of Pulp after Exposure by a Crown Fracture, Partial Pulpotomy, and Clinical Diagnosis of Healing

Miomir Cvek, DMS, PhD, and Margareta Lundberg, DDS

Pulps removed from a series of 21 crown-fractured incisors, which had been treated by partial pulpotomy and which had been clinically judged as healed 12 to 95 months (mean 52 months) after treatment, were examined histologically. In five pulps a few, scattered lymphocytes were seen, and in one pulp there was a slight infiltration with lymphocytes and a few plasma cells. In 10 pulps calcifications were present, either round with a laminated structure or irregular with an amorphous appearance. A moderate decrease in the number of cells and a moderate increase in collagen content were present in a portion of five pulps.

In a previous study a high frequency of pulpal healing was reported after partial pulpotomy and dressing with calcium hydroxide of pulps exposed by an accidental crown fracture (1). Criteria for such treatment were the presence of vital and/or hyperplastic tissue at the exposure site and no signs of luxation injury. Superficial layers of the pulp were removed by a gentle surgical technique (2) to a depth of about 2 mm below the level of the exposure. This was the depth of inflammatory reactions found in pulps of experimentally fractured monkey incisors at intervals up to 7 days after exposure (3). Healing to the procedure was evaluated using clinical and radiographic criteria. Sensitivity of the pulp and continuity of hard tissue in the exposed area were tested for clinically. Radiographically, the teeth were evaluated with respect to the presence of pathological changes, the formation of a hard tissue barrier, and the continued root development of immature teeth.

Since partial pulpotomy involves only a limited loss of pulp and crown substance, the need for pulpectomy and a post retained restoration of the crown is not required for the majority of treated teeth. It is, therefore, important that the value of clinical diagnosis of pulpal healing in these teeth be assessed in order to avoid undertaking pulpectomy routinely as has been recommended for pulpotomy treated teeth, after development of the root had been completed (4).

The purpose of the present study then was to evaluate the histological appearance of pulps exposed by an accidental crown fracture that had been treated by partial pulpotomy and judged clinically healed after a minimum postoperative period of 12 months.

MATERIALS AND METHODS

The 21 teeth studied in the present investigation formed part of a series of 123 incisors which had been treated with partial pulpotomy at Eastman Institute in Stockholm between 1963 and 1979 following accidental crown fracture and exposure of the pulp. All teeth were maxillary incisors, that had sustained a crown-root fracture or loss of crown substance to such an extent that pulpectomy and post were necessary for restoration of the crown.

The pulpotomy was performed 1 to 192 h (mean 29 h) after the injury, with a diamond bur in an air turbine, using short cutting periods and ample flushing of the instrument and the exposure area with sterile saline. After pulpal bleeding had stopped spontaneously, a dressing of calcium hydroxide (Calasept, Scania Dental AB, Knivsta, Sweden) was placed over the wound and the crown was restored with a composite material using an acid-etch technique. At the time of treatment, 13 teeth had immature roots while eight were mature. Distribution of the material is shown in Table 1.

Following pulpotomy the teeth were assessed after 3, 6, and 12 months and then annually. During the follow-up period, six teeth were involved in additional injuries so that previous restorations of the crowns were lost or fractured and had to be replaced. At the end of the follow-up period teeth were judged clinically as healed if they met the following clinical and radiographic criteria: (a) no clinical symptoms; (b) no radiographically demonstrable intraradicular or periradicular pathological change; (c) a continuous hard tissue barrier at the site of surgical excision, radiographically seen and clinically verified; (d) continued root development of immature roots; and (e) sensitivity to electric stimulation.

Pulpectomy was performed 12 to 95 months (mean 52 months) after the pulpotomy treatment when the

TABLE 1. Distribution of 21 crown-fractured incisors according to the tooth maturity and occurrence of crown-root fracture at the time of injury; time intervals: between injury and pulpotomy treatment (hours); additional accidental injury and pulpectomy (months); pulpotomy treatment and pulpectomy (months); and histological observations in the removed pulps*

Teeth	12	12	11	11	11	11	11	11	11	11	11	21	21	21	21	21	21	21	22	22		
Maturity of the tooth	I	I	I	I	I	I	I	I	M	M	M	I	I	I	I	M	M	M	M	I	M	
Crown-root fracture	†		†	†	†	†			†			†			†							
Interval from accident to pulpotomy (h)	4	24	48	3	54	14	40	72	17	19	16	49	24	192	2	1	2	4	15	24	4	
Additional injury pulpectomy (m)	17		19									10	44	24			10					
Interval from pulpotomy to pulpectomy (m)	80	28	84	50	55	44	35	95	12	85	53	65	48	60	39	64	42	24	48	58	24	
Histological observations																						
Lymphocytes	f		f							f		f									s	
Plasma cells																					f	
Calcifications	L		LA						LA	L	LA	L	LA			LA	LA				A	
Number of cells	n	n	n	n	n	n	n	md	n	n	n	md	md	md	n	n	n	n	n	n	md	n
Collagen content	n	n	n	n	n	n	n	mi	n	n	n	mi	mi	mi	n	n	n	n	n	n	mi	n

* Maturity of the tooth: I, immature; M, mature. Inflammatory cells: f, few, scattered; s, slight infiltration. Calcifications: L, laminated; A, amorphous. Cellular and collagen content: n, normal or nearly normal; md, moderate decrease in number of cells; mi, moderate increase of collagen content.

patients were 14 to 19 yr old. During preparation of the access cavity for the pulpectomy, care was taken to ensure that as little pulp tissue as possible was lost during the removal of the dentin and/or the hard tissue barrier. The pulp was cut about 1 mm from the apex with a blunted Hedström file, after which the pulp was removed from the pulp chamber with a barbed broach using the path previously made by the file. The pulps were fixed in 10% neutral buffered formalin, embedded in celloidin-paraffin and sectioned serially. Sections were cut to a thickness of 5 to 6 μm and stained with hematoxylin and eosin. Light microscopy was used for evaluation.

The pulps were classified according to the presence and number of inflammatory cells as follows: (a) pulps with no inflammatory cells; (b) pulps with a few, scattered inflammatory cells; and (c) pulps with an infiltration of inflammatory cells. In respect to cellular and collagen content the pulps were compared with pulp tissue of intact teeth that had been extracted for orthodontic reasons. Following comparison the pulps were judged as (a) pulps with normal cellular and collagen content and (b) pulps with a moderate decrease in number of cells and a moderate increase in collagen content.

RESULTS

The histological observations are presented in Table 1.

Inflammatory cells were seen in six pulps, and in five of these, there were only a few, scattered lymphocytes. In the remaining pulp a slight infiltration with lymphocytes was observed adjacent to a blood vessel, while further away there were a few plasma cells. Five of the pulps containing inflammatory cells had been

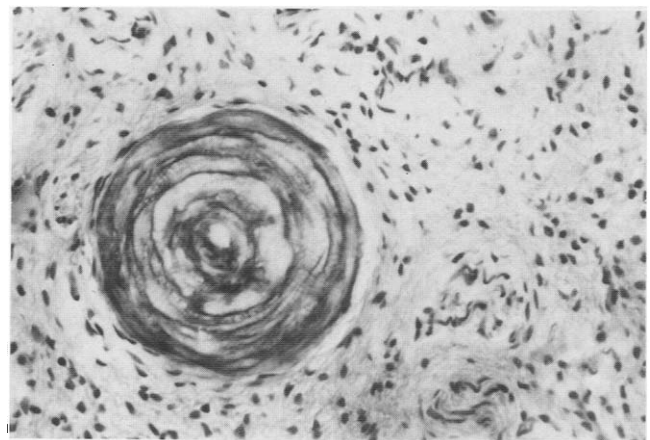


Fig 1. Round calcification with a laminated structure (original magnification × 200).

removed from teeth which had suffered an additional injury. Three of these had had a crown-root fracture where the subgingivally exposed dentin was not covered with temporary crown restoration during the follow-up period.

Calcifications were seen in 10 pulps. These calcifications were either round with a laminated structure (Fig. 1) or irregular with an amorphous appearance (Fig. 2). The round, laminated calcifications or pulpal denticles, which were observed as single (Fig. 3) or in a group (Fig. 4), varied in size, and, at most, one single denticle occupied approximately one-half of the pulpal width in the radicular part of a pulp. Irregular, amorphous and darkly stained formations which resembled dystrophic calcifications were smaller, about capillary size or sometimes slightly larger. These calcifications were usually seen adjacent to the walls of blood vessels, several in the same pulp but never in

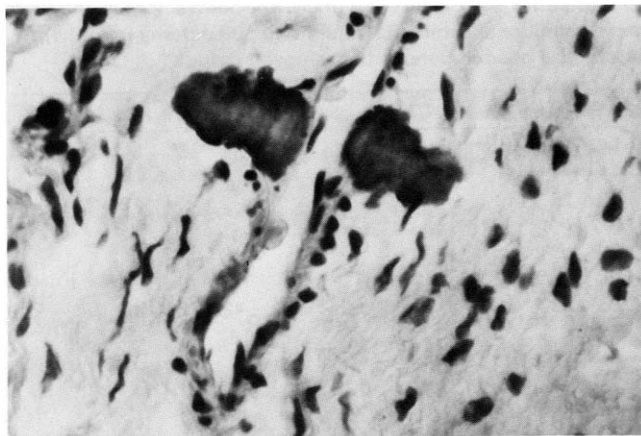


FIG 2. Irregular, darkly stained calcifications of amorphous appearance adjacent to the walls of a blood vessel (original magnification $\times 400$).

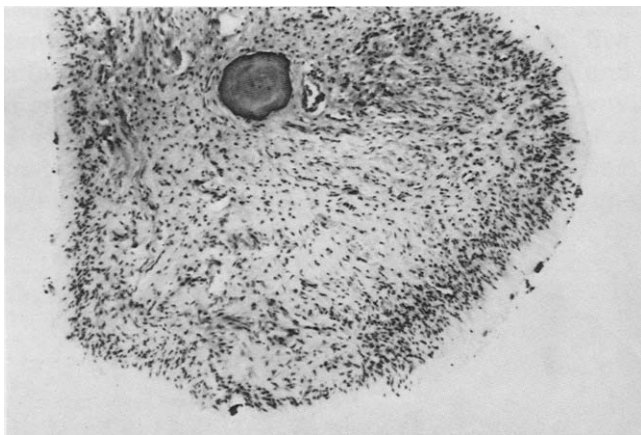


FIG 3. Coronal part of a pulp with a normal cellular and collagen content and a single pulp denticle (original magnification $\times 50$).

large numbers (Figs. 2 and 5). No reactions to calcifications were observed in the surrounding tissue.

The cellular and collagen content was judged as normal or nearly normal in 16 pulps (Figs. 3 to 5). A moderate decrease in number of cells and a moderate increase of collagen content was present in the apical portion of four pulps. In the remaining pulp these changes were more pronounced and present in most of the pulp.

DISCUSSION

Since pulpotomy-treated and clinically healed permanent teeth are not usually available for histological examination, the pulps removed from such teeth must be used for histological evaluation of pulpal healing. Removal of the pulp, however, implies that some of the pulp tissue must have been unavoidably lost when access into the pulp chamber was made. The present results should, therefore, be evaluated bearing in mind the possibility that an inflammatory change may have been present in the lost tissue layers.

The changes observed in the pulps of the present material—i.e. the presence of lymphocytes and in one instance plasma cells, calcifications, and changes in the cellular and collagen content—do not seem to differ in extent or frequency from those found and recognized as normal histological variations in the pulps of intact or conservatively treated teeth (5–9). An explanation for the presence of these changes can only be speculative since, besides the initial injury and treatment, various other factors could have been responsible. For example, three of the six pulps containing inflammatory cells were removed from crown-root-fractured teeth in which the subgingivally exposed but not covered dentin could have been the reason for the slight irritation of the pulps. Furthermore, five of these pulps were removed from teeth involved in additional injuries that may have also caused inflammation in the pulp. In animal experiments it has been shown that

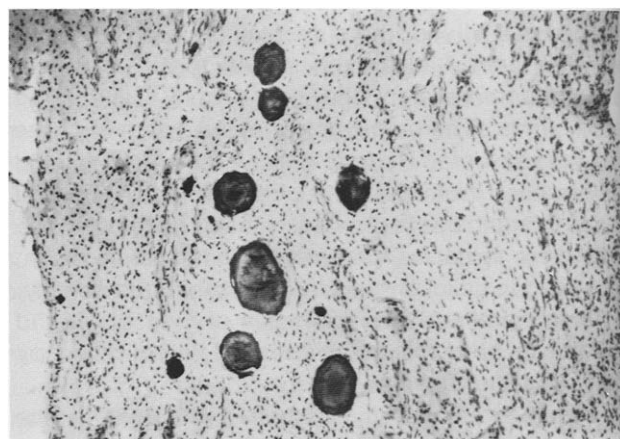


FIG 4. A group of denticles of similar size in the radicular part of a pulp (original magnification $\times 50$).

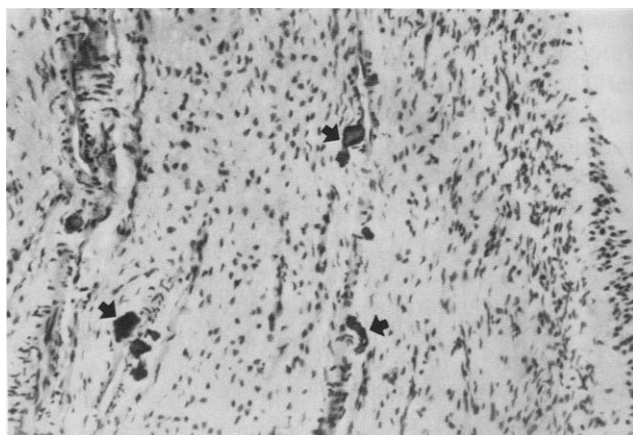


FIG 5. Average size and appearance of amorphous calcifications; note their relation to the blood vessels (original magnification $\times 100$).

inflammatory cells may be present in pulps several months after an injury (10).

It is generally agreed that no single clinical criterion can be regarded as proof of pulpal healing. Healing can, therefore, never be proven accurately by clinical means. However, it is logical to assume that the probability of a correct clinical diagnosis increases if several criteria are satisfied. Furthermore, the probability level or percentage of correct clinical assessment of healing may vary with preoperative conditions, such as in pulps exposed by caries or accident, and with treatment procedures, such as the surgical technique or the drug used as a pulp dressing. In the present material the clinical evaluation of healing corresponded well to histological conditions of examined pulps.

Summing up then, it is our opinion that the changes observed in the pulps of the present series of teeth do not represent sufficient histological evidence to support the use of routine pulpectomy after partial pulpotomy treatment of exposed pulps in accidentally crown-fractured teeth.

SUMMARY AND CONCLUSION

The purpose of investigation was to histologically assess clinically healed pulps which had undergone partial pulpotomy treatment for exposed pulps in crown-fractured incisors. The pulps were removed for prosthetic indications from 21 such incisors which were clinically judged as healed, 12 to 95 months after treatment. Histological observations confirmed

the clinical diagnosis of healing, and it was, therefore, concluded that the routine use of pulpectomy after partial pulpotomy treatment of exposed vital pulps in crown-fractured teeth does not appear justified.

This investigation was supported by a grant from Stockholms läns landsting, Tandvårdsnämnden, TA 8004-0604, 1980.

Miomir Cvek is Head and Margareta Lundberg is Senior Dental Officer at the Department of Pedodontics, Eastman Institute in Stockholm. Requests for reprints should be directed to Miomir Cvek, Department of Pedodontics, Eastmaninstitutet, Dalagatan 11, S-113 24 Stockholm, Sweden.

References

1. Cvek M. A clinical report on partial pulpotomy and capping with calcium hydroxide in permanent incisors with complicated crown fracture. *J Endodon* 1978;4:232-7.
2. Granath L-E, Hagman G. Experimental pulpotomy in human bicuspsids with reference to cutting technique. *Acta Odontol Scand* 1971;29:155-63.
3. Cvek M, Cleaton-Jones PE, Austin JC, Andreasen JO. Pulp reactions to exposure after experimental crown fractures or grinding in adult monkeys. *J Endodon* 1982;8:397-98.
4. Langeland K, Dowden WF, Tronstad L, Langeland KL. Human pulp changes of iatrogenic origin. *Oral Surg* 1971;32:943-80.
5. Gvozdenovic-Sedlecki S, Quist V, Hansen HP. Histologic variations in the pulps of intact premolars from young individuals. *Scand J Dent Res* 1973;81:433-40.
6. James VE. Early pulpal calcifications of permanent teeth of young individuals (abstr.) *J Dent Res* 1958;37:973.
7. Appleton J, Williams MJR. Ultrastructural observations on the calcification of human dental pulp. *Cal Tiss Res* 1973;11:222-37.
8. Sundell JR, Stanley HR, White CL. The relationship of coronal pulp stone formation to experimental operative procedures. *Oral Surg* 1968;25:579-88.
9. Seltzer S, Bender IB. *The dental pulp: biologic considerations in dental procedures*. 2nd ed. Philadelphia: JB Lippincott, 1975.
10. Seltzer S, Bender IB, Kaufman IJ. Histologic changes in dental pulps of dogs and monkeys following application of pressure, drugs, and microorganisms on prepared cavities. Part II. Changes observable more than one month after application of traumatic agents. *Oral Surg* 1961;14:856-67.