

REVIEW

Healing of Surgical Wounds in Oral Mucoperiosteal Tissues

John W. Harrison, DMD, MS

This report provides a review of the major biological events that occur in the oral mucoperiosteal tissues following simple surgical wounding. The chronological sequence and interrelationships of mucoperiosteal tissue wound healing responses are described. The objectives of this review are to provide clarification of wound healing terminology and a basic reference source for further investigative research into the wound healing responses to endodontic surgery.

A wound is defined as any injury which causes disruption of the anatomical continuity and/or function of living tissues and results in cellular injury and death (1). All surgical procedures involve intentional wounding of specific tissues and are dependent upon the wound healing responses of those tissues for success. Wound healing is, in turn, dependent upon the type of tissues wounded and the type of wound inflicted. Therefore, the surgeon must know the anatomy and physiology of the operated tissues, and the responses of those tissues to various types of surgical wounding. With this knowledge, surgical techniques that best promote rapid wound healing responses can be employed.

Periodontists have extensively investigated wound healing responses to periodontal surgical procedures and, as a result, have developed and refined their surgical concepts and techniques to enhance rapid wound healing, which is the goal of every surgical procedure. By contrast, endodontists have contributed little to the investigative knowledge relating to wound healing following endodontic surgery. This lack of investigative research is probably due to the perception that periodontal wound healing studies are directly applicable to endodontic surgery. The existence of this perception is reinforced by the fact that almost every surgical concept and technique currently utilized in endodontic surgery is derived from evidence relating to wound healing responses following periodontal surgery. Direct extrapolation of such evidence to endodontic surgery may be greatly misleading because of fundamental differences between the two types of surgery in the require-

ments for soft and osseous tissue manipulation and in the potential for primary versus secondary intention healing. Although both involve reflection of mucoperiosteal flaps, the periodontist is excising diseased gingival tissues, curetting root surfaces, removing and recontouring radicular and interdental bone, apically positioning the flapped tissues, and relying almost exclusively upon secondary intention healing. These surgical procedures differ markedly from endodontic surgical procedures which may heal by primary intention. There is a difference in the types of tissues injured and the types of surgical wounds inflicted. As tissue wound-healing responses are dependent upon these two variables, it is logical to assume that wound-healing responses to endodontic surgery are not the same as for periodontic surgery. This is further confirmed by the much higher potential for primary intention healing in endodontic surgery. Thus, there is a need for investigative research relating specifically to endodontic surgical wound healing in order to evaluate and develop surgical concepts and techniques which are most conducive to rapid wound healing.

A series of wound-healing studies have been conducted at Baylor College of Dentistry and will be reported later. These articles will define the chronological and qualitative biological events that occur following various periradicular surgical procedures and, based upon these findings, recommend specific alterations in some currently accepted concepts and surgical techniques.

The purposes of the present report are (a) to provide a review of the major biological events that occur in the healing responses of oral mucoperiosteal tissues to simple surgical wounding, and (b) to serve as a basis for subsequent reports detailing the complex wound-healing responses of the various soft and hard tissues of the periodontium to periradicular surgery. Objectives of this review are to describe the chronological sequence and interrelationships of oral mucoperiosteal tissue wound healing responses, provide clarification of wound-healing terminology, and provide a basic reference source (annotated version available) for further investigative study and research of wound-healing responses to endodontic surgery.

ORAL MUCOPERIOSTEAL WOUND HEALING

From a review of the medical, dental, and basic science literature, it is apparent that wound healing is dependent upon: (a) the type of tissue wounded and (b) the type of wound the tissue receives (1, 2).

Tissues of the same type generally respond similarly to wounding (e.g., epidermis and oral epithelium respond to wounding in a similar manner, as do dermis and gingival lamina propria). However, there are important temporal and qualitative differences between skin and oral soft tissues in the similar biological events that occur in the wound-healing process. These differences explain the clinical observation that oral soft tissues heal much faster than skin but, perhaps more importantly, they underscore the necessity for very cautious extrapolation of evidence from wound-healing studies of non-oral tissues to oral tissues.

There are various types of surgical wounds, each causing different wound-healing responses in a particular tissue. For example, incisional wounds elicit a different response than excisional wounds, with the latter healing at a slower rate and by secondary rather than primary intention. Primary intention healing results when wound edges are closely approximated, separated only by a thin clot. The end result of this healing mechanism is known as *regeneration*, and the wounded tissues are ultimately restored to a normal anatomical pattern and function (1, 2). Secondary intention healing results when wound edges are not approximated and the formation of a considerable amount of granulation tissue is necessary to bridge the hiatus. The end result of this healing mechanism is known as *repair* and normal anatomy and/or function are not restored (1, 2). In the oral soft tissues, secondary intention healing results in scar tissue formation (3).

Wound healing involves a complex series of biological events; some occurring simultaneously and others dependent upon the completion of prior events. Surgical wounding sets into motion a series of vascular, cellular, and biochemical mechanisms which lead to regeneration or repair (4-6). All of these mechanisms are mobilized in the surgical wounding of the oral mucoperiosteal tissues, which include the gingiva, alveolar mucosa, palatal mucosa, and the periosteum underlying these tissues.

It is the incisional wounding of mucoperiosteal tissues, allowing reapproximation of like tissues (i.e., epithelium to epithelium and fibrous connective tissue to fibrous connective tissue), that provides the best descriptive source for reviewing the events of wound healing. The incision produces a *wound site* (area of discontinuity of vital tissues), bounded by *wound edges* (injured adjacent tissues with damaged cells, severed vessels and fibers, etc.) in the *wound area* (includes the wound site, wound edges, and adjacent uninjured tissues) (Fig. 1). The more relevant mechanisms precipitated by this type of surgical wounding of mucoperiosteal tissues will be described in four phases: (a) clotting and inflammation, (b) epithelial healing, (c) connective tissue healing, and (d) maturation and remodeling.

It is essential to stress that this is an artifactual separation of major wound-healing phases for descriptive purposes only. They are not separate and distinct entities, as considerable overlapping occurs, with several of these phases observable in the wound area at the same time.

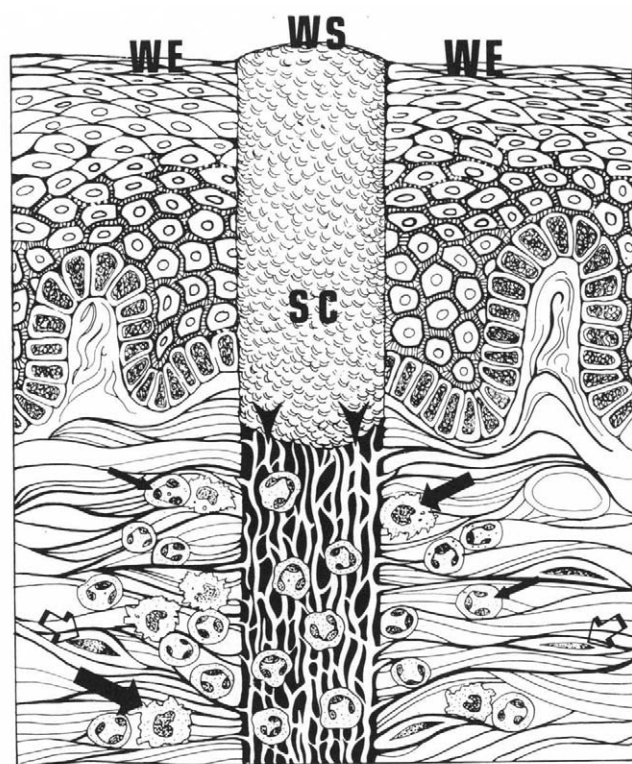


FIG 1. The incisional wound in mucoperiosteal tissues results in a wound site (WS) or area of discontinuity of vital tissues and wound edges (WE) comprised of injured tissues immediately adjacent to the wound site. A surface coagulum (SC) forms in the more superficial portion of the wound site and is the counterpart of a scab in dry epidermal wounds. Subjacent to the coagulum is a fibrin clot, with fibrin strands (arrowheads) that have undergone contraction and are oriented parallel to the plane of the wound. Polymorphonuclear leukocytes (small arrows) predominate in the fibrin clot occupying the wound site during the early stages of the inflammatory response as macrophages (large arrows) and reparative cells (open arrows) are mobilized for migration from the wound edges into the wound site.

CLOTTING AND INFLAMMATION

Surgical wounding causes disruption of the microvasculature supplying the mucoperiosteal tissues and the first requirement is to effect hemostasis, the arrested flow of blood. Vascular injury releases plasma fractions (albumin, fibrinogen, globulins, fibronectin, plasminogen, etc.) and formed elements (erythrocytes, platelets, and leukocytes) into the surrounding tissues. A plethora of humoral and cellular biochemical mediators are activated, causing vasodilatation and increased permeability in intact microvessels (primarily venules, precapillaries, capillaries, and small arterioles), and intravascular platelet aggregation (platelet plugs) in severed vessels. The activated biochemical mediators influence both the clotting and inflammatory mechanisms.

Clotting

Extrinsic and intrinsic clotting mechanisms are triggered, each giving rise to a cascading sequence of events leading to clot formation (4). The crucial step in both clotting mechanisms is the conversion of fibrinogen to fibrin and the polym-

erization and linkage of these molecules into interconnecting strands forming a thread-like network entrapping serum fractions and formed elements. This forms a hydrated, gelled aggregate termed the *fibrin clot* (1, 5). The fibrin clot forms extravascularly in the wound site and also intravascularly, strengthening the initial platelet plug and further stemming the extravasation of blood (3, 5).

The properly formed, thin fibrin clot is essential to rapid, primary intention healing and forms the initial seal between the oral environment and the wound edges of the injured mucoperiosteal tissues. A few hours after clot formation, the fibrin strands undergo contraction and become orientated parallel to the plane of the wound (1, 7). This provides a tenuous attachment between opposing wound edges (5) and forms pathways of migration, first for inflammatory cells and, subsequently, for cells which will effect repair or regeneration (8) (Fig. 1).

The importance of the thin fibrin clot in wound healing is made pointedly obvious when early hemostasis is not accomplished and blood continues to leak into the wound site. Healing is delayed by the formation of a *coagulum*, which is comprised of excessive amounts of serum, formed elements of blood, tissue debris, and irregular, disoriented, interrupted, widely spaced fibrin strands (Fig. 2). Its presence prevents formation of the initial seal and the establishment of migratory pathways. The coagulum occupies excessive space and is associated with inadequate reapproximation of wound edges, leading to second intention healing and scar formation (1, 5, 9). A large coagulum is clinically observable as a mucoid mass between gaping wound edges. If it forms between the flap and cortical bone, it is commonly referred to as a hematoma (3). Coagulum formation greatly inhibits wound healing because it acts as a barrier, as opposed to a pathway for inflammatory and reparative cells, and must first be resorbed before connective tissue healing can be initiated (2, 9).

Inflammation

The response of all living tissues to all forms of injury is inflammation, which involves vascular, humoral, and cellular reactions at the injury site and prepares the site for healing (3). Healing is dependent upon the inflammatory process to create a favorable environment for cellular metabolism by removing microorganisms, necrotic or damaged tissue, and particulate matter. Anything that markedly impedes the inflammatory response following surgical wounding (e.g., injection of steroids into the wound area) also impedes the healing mechanisms. Inflammation dominates the early events of wound healing. The regenerative or reparative events, which begin during the inflammatory phase, assume dominance later (6). The temporal relationship of these events is important in that the more rapidly the inflammatory process can create a favorable environment, the more rapidly healing can progress. Thus, it follows that the more favorable the environment resulting from the surgical procedure, the more rapidly the inflammatory process can create an environment conducive to rapid wound healing. Poor tissue reapproximation, excessive tissue injury during surgical manipulation, and prolonged retention of sutures in tissues are examples of surgical results which prolong the debridement activities of the inflammatory process and delay the onset of healing mechanisms.

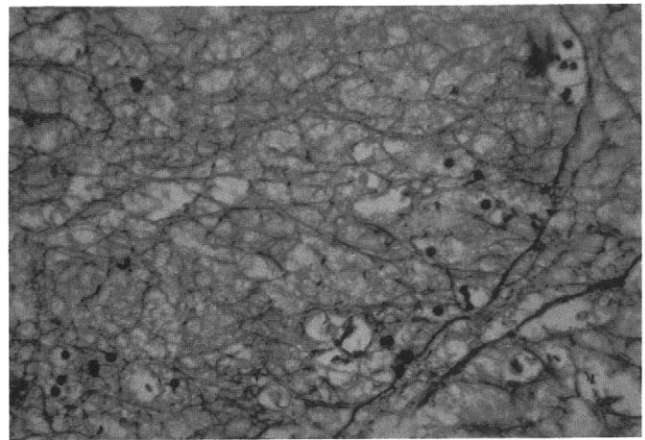


Fig 2. A coagulum in an incisional wound at 3 days following surgery. Note the widely spaced, disoriented fibrin strands and the paucity of inflammatory cells. Poor reapproximation of the mucoperiosteal wound edges has resulted in coagulum formation, delaying the migration of inflammatory and reparative cells into the wound site and, ultimately, delaying the wound-healing process.

Inflammation is a stereotyped, nonspecific response common to all types of injuries and to all tissues. It varies only in its magnitude, which is governed by the severity of the injury. The events of the inflammatory response are mediated by the production, activation, and release of a myriad of biochemical substances, known collectively as inflammatory mediators, which are tightly sequestered within cells or are present in plasma or tissues as precursor forms that must go through sequential reactions before becoming activated (10). The mediators of the various components of the inflammatory response are still under intensive investigation regarding the plethora of interrelated mechanisms and feedback systems involving the amine, kinin, complement, fibrinolytic, arachidonic acid, lysosomal, lymphocytic, and mononuclear phagocytic systems, among others (4, 10, 11).

The interactions between inflammatory mediators are extremely complex, with almost every major system listed above having potentiating or activating effects on several other major systems. Fortunately, there is an equally complex, but highly effective, system of checks and balances, allowing destruction or inactivation of released mediators. Without the latter, inflammation would become a never ending, self-perpetuating, totally destructive process (6).

As a result of surgical wounding, the inflammatory mediators cause hemodynamic changes in the microvasculature, resulting in vasodilation, an increased blood volume (engorgement), and a decreased rate of flow. The microvascular walls, particularly in postcapillary venules, become increasingly permeable due to the action of histamine and 5-hydroxytryptamine (serotonin) which induce contraction of endothelial cells and disrupt the fenestral diaphragms covering the normal gaps between endothelial cell attachments. This results in an outpouring of a protein-rich fluid (exudate) containing albumin, complement, globulins, fibrinogen, fibronectin, kinins, and other plasma macromolecules into the surrounding tissues. As engorgement of the microvascular bed occurs, leukocytes become displaced to the periphery of the blood stream (margination) because the red blood cells become adherent to

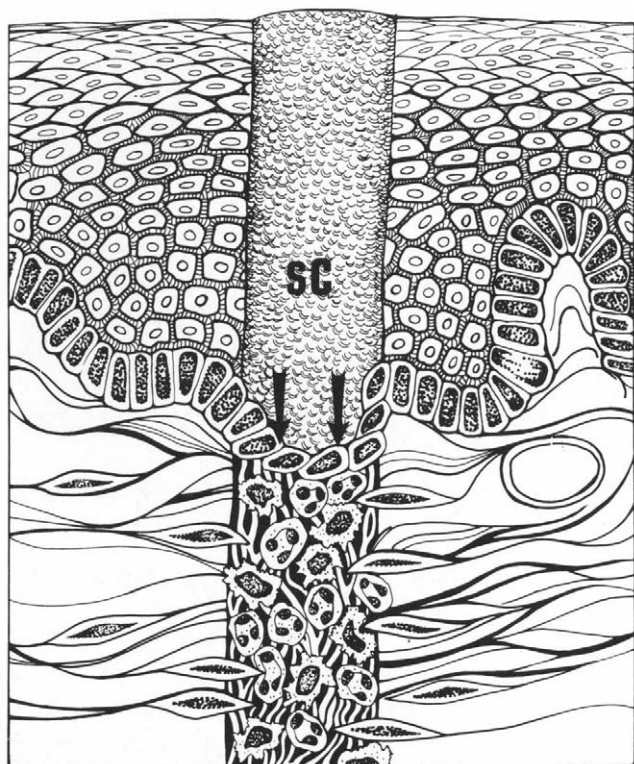


FIG 3. Epithelial cells of the basal layer undergo dedifferentiation and migrate across the fibrin strand scaffolding beneath the surface coagulum (SC) to contact cells from the opposing wound edge to form an epithelial seal (arrows). Macrophages are replacing polymorphonuclear leukocytes as the predominant inflammatory cell in the wound site. Reparative cells (fibroblasts and undifferentiated ectomesenchymal cells) are migrating into the periphery of the wound site and initiating synthesis of ground substance and fibrous proteins (collagen).

each other (sludging), and form aggregates of cells (rouleaux) which are larger than the individual leukocytes. The leukocytes are displaced from the central axis of the slowly moving stream. The displaced leukocytes begin to adhere to the surrounding endothelial cells of the vascular wall (pavementing) and actively pass through the vessel wall (emigration) and proceed to the wound site (migration) by amoeboid motion (diapedesis). This active movement of leukocytes is under the influence of an increasing gradient of chemoattractants (inflammatory mediators) in the tissue injury site and is termed *chemotaxis* (3, 12).

The first wave of leukocytes is largely comprised of polymorphonuclear neutrophils (PMN's) which are the most active cells in the early inflammatory response, phagocytizing microorganisms, particulate matter, and cellular debris (4, 13) (Fig. 1). The primary function of PMN's is destruction of microorganisms and their by-products. This process is especially important in surgical wounding of the oral tissues, as sterility cannot be obtained in this environment and microorganisms must be quickly destroyed before true infection is established. Rapid destruction of microorganisms quickly reduces the need for continued migration of these cells (4) and the chemotactic mechanisms responsible for their early migration are soon deactivated. Under ideal wound-healing con-

ditions, PMN activity subsides and their numbers decrease rapidly between 24 and 48 h after wounding (4).

After the initial influx of PMN's, plasma-derived monocytes appear in increasing numbers, undergoing rapid morphological and functional changes under the influence of inflammatory mediators to become activated macrophages, which become the major contributors to initial wound-healing activity (1, 11, 14), and soon become the predominant cell in the wound site (8) (Fig. 3). Macrophages, unlike PMN's, are essential to the temporal and qualitative course of healing (15), releasing biochemical mediators which stimulate fibroblast mitogenesis and migration, collagen and ground substance synthesis, and angiogenesis. The remarkable macrophages are the supervisors of the reconstruction of damaged tissues, controlling the extent and degree of the immediate inflammatory response, creating an environment in which connective tissue healing can occur, and directing the ingress of cells (fibroblasts, undifferentiated ectomesenchymal cells, endothelial and smooth muscle cells) that will effect repair or regeneration of the wound site (1, 8, 10, 16). Although PMN's initiate the phagocytic activity, macrophages are far more efficient and inclusive in their scavenging ability.

The clotting and inflammatory mechanisms of phase 1 of the wound-healing process set the stage for connective tissue healing and, under optimal conditions, the newly migrated fibroblasts and undifferentiated ectomesenchymal cells begin synthesis of ground substance and collagen molecules in the wound site. However, for connective tissue healing to progress rapidly and efficiently, a more impervious barrier than the fibrin clot is needed to protect the wound site from the toxic elements of the oral cavity environment. This barrier is formed by epithelium and the speed with which it forms affects the rate of progression of underlying connective tissue healing, determining to a large extent whether repair or regeneration occurs (1-3, 17).

EPITHELIAL HEALING

Epithelial cells in the wound edges undergo specific changes within hours after surgical wounding. The basal and suprabasal prickle cells undergo dedifferentiation, acquire the potential for amoeboid movement, and develop phagocytic capabilities (1, 2, 5, 14, 17, 18). Spaces appear between these cells as desmosomal attachments are loosened. The cells become elongated and begin to migrate across the fibrin scaffolding of the clot, dissecting their way between the well-formed fibrin clot and the surface coagulum (counterpart of the scab in dry epidermal wounds) (14). The basal and suprabasal cells adjacent to these migrating cells of the wound edge subsequently begin to undergo mitosis at a rate greatly exceeding normal, providing daughter cells to replenish the source of the migrating epithelial cells.

The migrating cells move as a monolayer or sheet of cells, which may be several cells in thickness, toward the center of the surface of the wound until cellular contact is made with epithelial cells migrating from the opposing wound edge (2, 18). The movement of monolayers or sheets of elongated epithelial cells during this migration is referred to as *streaming*. The paths of the migrating cells are guided by the orientation of the fibrin substrate (contact guidance) and movement direction changes only when initial contact is made

with another like cell. Migration stops only when the cell is in contact on all sides with other epithelial cells (contact inhibition).

Contact of the opposing epithelial cells from the wound edges establishes the *epithelial seal* (or epithelial bridge) (7, 17) (Fig. 3). Once the seal is established, the epithelial cells differentiate, undergo mitosis at an accelerated rate, and soon reform the definitive layers of stratified squamous epithelium through the process of maturation (1, 2, 14). With stratification or layering, an effective *epithelial barrier* now exists and underlying connective tissue healing can progress without interference from the irritants of the oral cavity (5, 17) (Fig. 4 to 6).

In addition to preventing the ingress of oral irritants, the epithelial barrier is of clinical significance for two other reasons. The barrier inhibits the loss of tissue fluids, which are the source of nutrients for the connective tissue cells which will effect repair. It thus greatly enhances healing by maintaining tissue hydration (5). And, it is the epithelial barrier that provides a tremendous increase in wound strength (i.e. resistance to dislodgement or separation of the wound edges) (3, 9).

CONNECTIVE TISSUE HEALING

The connective tissue healing phase is the most complex of the wound healing phases. It begins with the formation of the epithelial seal and progresses rapidly after epithelial barrier formation. The primary connective tissue cell involved in this phase is the fibroblast which synthesizes ground substance and collagen, the essential elements of regeneration or repair (5, 16). As macrophages become the predominant cell in the wound site during the inflammatory stage and continue the scavenging and phagocytosis initiated by the PMNs, they release factors that cause the mobilization and migration of fibroblasts into the area (2, 14). Fibroblasts are mobilized primarily from undifferentiated ectomesenchymal cells in the perivascular tissues surrounding the wound site (4). Both of these cell types are attracted to the wound site and, if the environment permits, begin the synthesis of glycosaminoglycans, glycoproteins, and fibrous proteins (Fig. 4). The reparative cells first entering the avascular wound site are dependent upon the diffusion of nutrients from the microvasculature in the wound edges for synthesis and survival (15, 16). The first-formed collagen appears as a fine, branching network of delicate type III (reticulin) fibers formed by undifferentiated ectomesenchymal cells and by young fibroblasts. The latter cells soon initiate synthesis of type I collagen. As collagen molecules enter the extracellular environment, angiogenesis factors are released from macrophages and other sources, stimulating the migration of endothelial and smooth muscle cell chords from the microvasculature of the wound edges into the wound site (1, 8, 15, 16). Lumina develop in these chords and new vessels (neovasculature) are formed within the periphery of the wound site and, subsequently, angiogenesis proceeds toward the central area of the site (16). However, this neovasculature is highly inefficient; with irregular and turbulent blood flow, tortuous routes, and excessive permeability (5, 19). The development of a mature, efficient microvascular system (revascularization) is dependent upon the maturation of endothelial cells which is, in turn, dependent

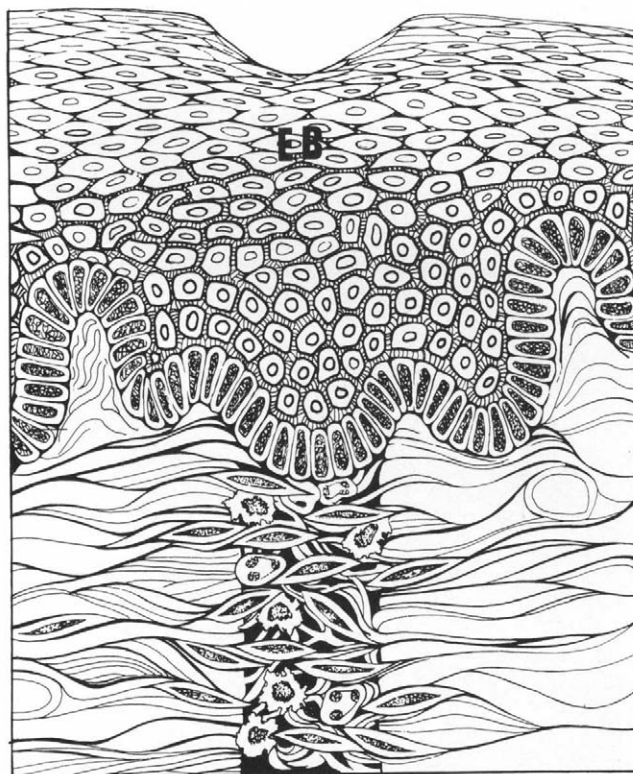


FIG 4. The epithelial cells forming the epithelial seal differentiate, undergo rapid mitosis, and reform the definitive layers of stratified squamous epithelium to form an epithelial barrier (EB). Macrophages are the predominant inflammatory cell as a result of the diminishing presence of polymorphonuclear leukocytes. Fibroblasts and undifferentiated ectomesenchymal cells are seen throughout the wound site as synthesis of ground substance and collagen, accompanied by angiogenesis, results in replacement (organization) of the fibrin clot by young connective (granulation) tissue.

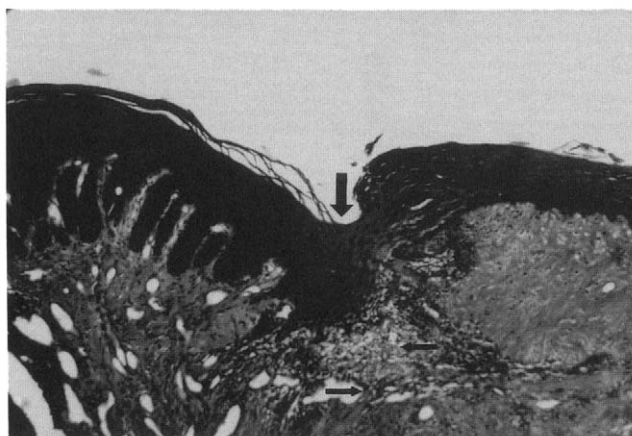


FIG 5. Epithelial barrier formation is seen in incisional wound site (large arrow) a few days following surgery. The fibrin clot in the lamina propria has been replaced with granulation tissue (small arrows) (hematoxylin and eosin; original magnification $\times 33$).

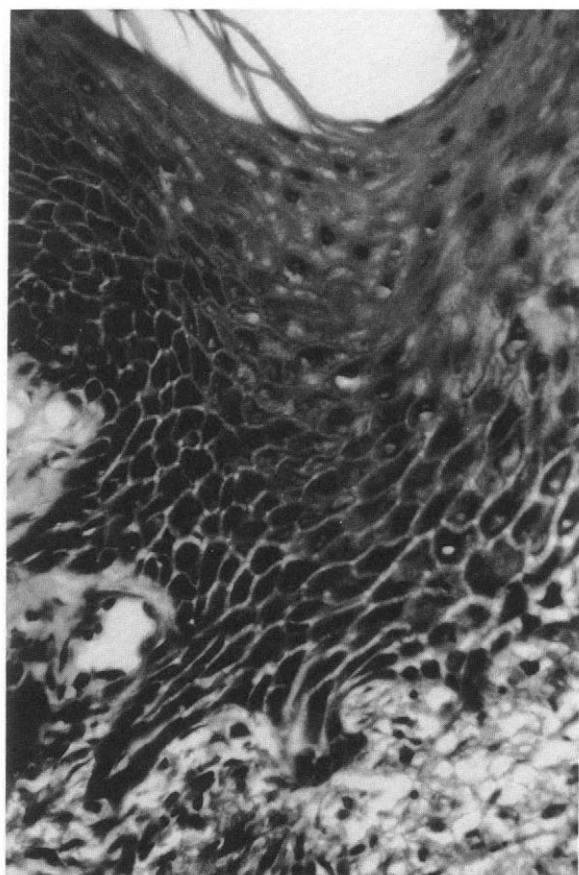


FIG 6. Higher power view of epithelial barrier seen in Fig. 5. Note that all layers or strata of stratified squamous epithelium can be identified (hematoxylin and eosin; original magnification $\times 132$).

upon continuous collagen and matrix formation by fibroblasts (3, 5, 19).

Thus, the interdependent mechanisms of fibroplasia (collagen synthesis), angiogenesis, continued fibroplasia, and revascularization determine the temporal and qualitative course of connective tissue healing (15). These mechanisms are, in turn, dependent upon the clotting and inflammatory phase and the epithelial healing phase for progress (3).

As wound healing progresses, the ratio of macrophages to fibroblasts decreases and the fibroblast becomes the predominant cell in the healing wound site (8, 16). The transition from a tissue with a predominant inflammatory infiltrate, termed *granulomatous tissue*, to a highly vascular tissue with fibroblast predominance, termed *granulation tissue* (Fig. 7), signals the successful progress of connective tissue healing. The granulation tissue is at first loosely organized because of an abundance of ground substance and weak collagenation, but gradually acquires increasing collagen maturation and gelation of ground substance (5). At this stage, the fibrin clot has been replaced by young connective (granulation) tissue and *organization* of the clot is considered to be complete (1, 3). The granulation tissue continues its maturation with aggregation of collagen through increasing protein-polysaccharide cross-linkages and continued gelation of ground substance to become a more mature fibrous connective tissue (Fig. 8). At this point, the wound site can be distinguished

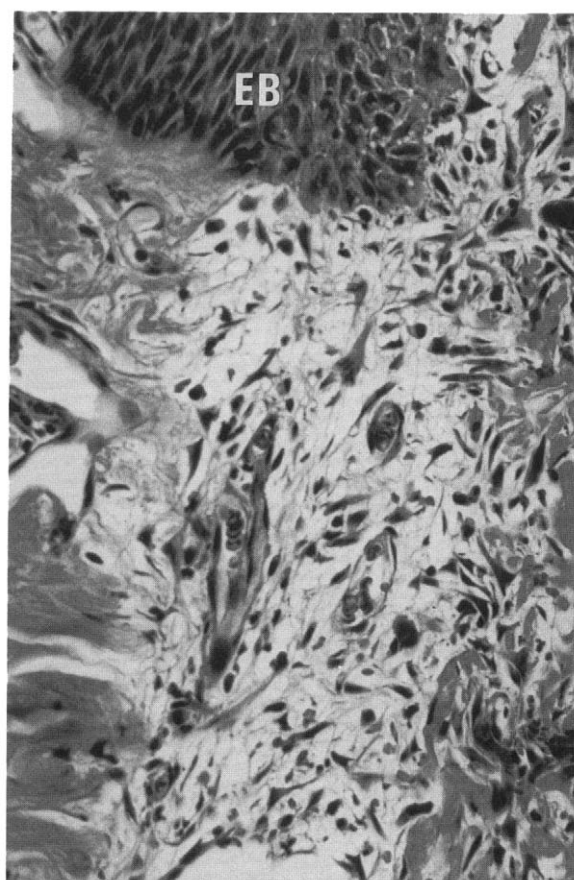


FIG 7. Granulation tissue has replaced (organized) the fibrin clot in the incisional wound site. Reparative cells predominant and neovasculation is evident. Basal and prickle cell layers of the epithelial barrier (EB) are identifiable at top (hematoxylin and eosin; original magnification $\times 132$).

from normal mucoperiosteal tissue by thinner, less dense fibers and a greater number of fibroblasts per unit area. It remains for the maturation and remodeling phase to create an architectural pattern of normalcy.

MATURATION AND REMODELING

After sufficient collagen is produced, the number of fibroblasts in the former wound site decreases and there is a concomitant reduction in the vascular channels. This signals the end of the connective tissue healing phase and the beginning of the maturation and remodeling phase. Under ideal healing conditions the later phase may begin as early as a few days after simple incisional wounding in oral mucoperiosteal tissues. These new collagen fibers are highly soluble (14) and, during the maturation phase, undergo pronounced changes in form, bulk, strength, and orientation, but the collagen content or mass remains essentially the same (20). Maturation involves simultaneous collagen deaggregation (depolymerization) and reaggregation (polymerization) which results in a change in the architecture of the fibers to an organized pattern and density similar to those of normal adjacent tissues (20) (Fig. 9). Maturation and remodeling result in progressive fiber strength, size, and insolubility through intramolecular and

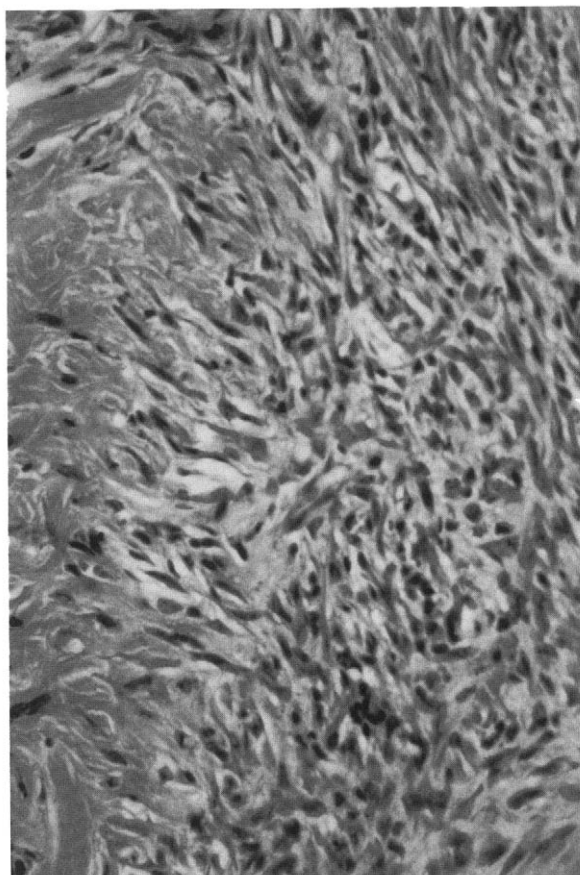


FIG 8. Granulation tissue in the incisional wound site is replaced by a more mature fibrous connective tissue as collagenation progresses. Note the heavy influx of fibroblasts and fibroblast-like cells. Normal tissue architecture is observable at the *left* (Hematoxylin and eosin; original magnification $\times 132$).

intermolecular cross-linking among collagen macromolecules, fibrils, and fibers (7, 14). As the fiber pattern and density take on a normal appearance, the fibroblast population decreases to the same level as adjacent tissues (Fig. 10). The length of time from beginning to end of this phase is undetermined. However, as lamina propria of mucoperiosteal tissues continuously undergoes a remodeling process in response to normal physiological stresses, it is likely that the completion of this phase is simply a gradual slowing of the process to a normal rate (3).

SUMMARY

Wound healing in the oral mucoperiosteal tissues is a result of a complex series of interrelated biological events and occurs, under proper conditions, with remarkable speed and efficiency. The primary events resulting from simple surgical wounding of these tissues have been reviewed by dividing the wound healing mechanisms into four major phases. It is again emphasized that all of these phases may be occurring in the same wound site at the same time.

In periradicular surgery, there are three different types of wounding; incisional, dissectional, and excisional. Each of

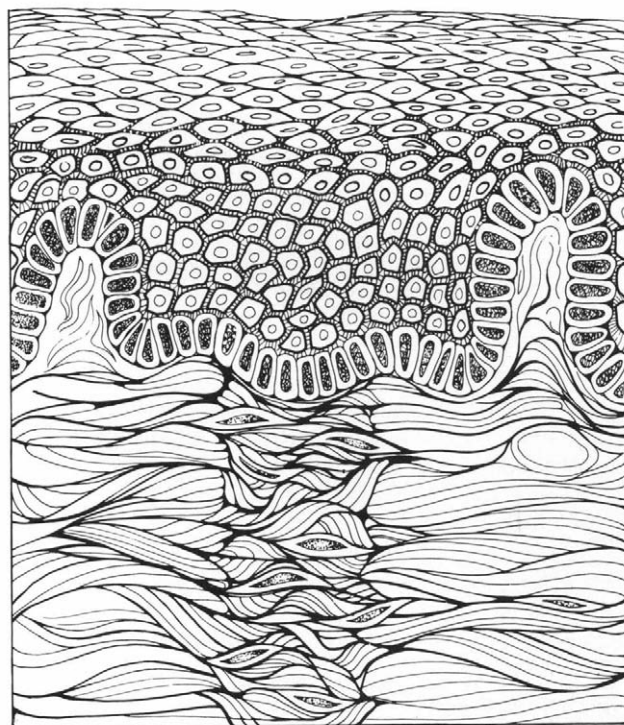


FIG 9. After sufficient collagen is produced in the wound site, maturation and remodeling occurs. The highly soluble young collagen undergoes deaggregation and reaggregation, increasing its size, strength, and insolubility through progressive cross-linkage among macromolecules, fibrils, and fibers. The number of fibroblasts and vascular channels decreases, and the maturation and remodeling of collagen will result in an architectural pattern and density similar to normal adjacent tissues.

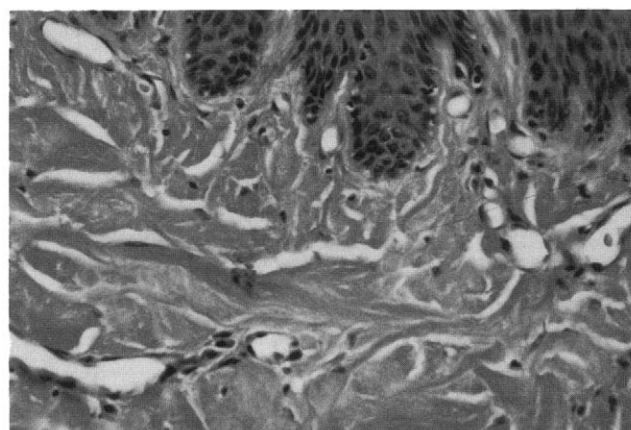


FIG 10. Maturation and remodeling has resulted in a normal tissue architectural pattern 2 months after surgery. The former incisional wound site is in the center of the field of this photomicrograph (hematoxylin and eosin; original magnification $\times 66$).

these wounds causes injury to different tissues of the periodontium and, thus, each results in a different wound-healing response (3). The temporal and qualitative healing responses to periradicular surgical wounding at various postsurgical intervals have been investigated using the rhesus monkey as a research model. The present report is designed to serve as a

reference source and descriptive base for the events to be described in later reports detailing the wound-healing response of oral tissues to periradicular surgery.

The author thanks Miss Pam Keel for her meticulous care in the preparation and editing of this manuscript.

Dr. Harrison is professor and director of the advanced education program in endodontics at Baylor College of Dentistry. Address requests for reprints to Dr. John W. Harrison, Baylor College of Dentistry, 3302 Gaston Avenue, Dallas, TX 75246.

Editor's Note. A completely annotated version of this article citing 77 additional reference sources is available from *Journal of Endodontics* editorial office.

References

1. Krawczyk WS. Wound healing in the oral cavity. In: Shaw JH, Sweeney EA, Cappuccino CC, et al. eds. *Textbook of oral biology*. Philadelphia: WB Saunders, 1978:937-54.
2. Melcher AH. Healing of wounds in the periodontium. In: Melcher AH, Bowen WH, eds. *Biology of the periodontium*. London: Academic Press, 1969:499-529.
3. Harrison JW, Gutmann AL (eds.). *Surgical wound healing*. Surgical endodontics. Boston: Blackwell Scientific Publications, 1991:300-37.
4. Boucek RJ. Factors affecting wound healing. *Otolaryngol Clin North Am* 1984;17:243-64.
5. Ruben MP, Smukler H, Schulman SM, Kon S, Bloom AA. Healing of periodontal surgical wounds. In: Goldman HM, Cohen DW, eds. *Periodontal therapy*. 5th ed. St. Louis: CV Mosby, 1980:640-754.
6. Robbins SL, Kumar V. Inflammation and repair. In: Robbins SL, Kumar V, eds. *Basic pathology*. 4th ed. Philadelphia: WB Saunders, 1987:28-61.
7. Ordman LN, Gillman T. Studies in the healing of cutaneous wounds. Part III. A critical comparison in the pig of the healing of surgical incisions closed with sutures or adhesive tape based on tensile strength and clinical and histologic criteria. *Arch Surg* 1966;93:911-28.
8. Hunt TK, Knighton DR, Thakral KK, Goodson WH, Andrews WS. Studies on inflammation and wound healing: angiogenesis and collagen synthesis stimulated in vivo by resident and activated wound macrophages. *Surgery* 1984;96:48-54.
9. Hiatt WH, Stallard RE, Butler ED, Badget B. Repair following mucoperiosteal surgery with full gingival retention. *J Periodontol* 1968;39:11-6.
10. Ryan GB, Majno G. Acute inflammation. A review. *Am J Pathol* 1977;86:183-276.
11. Trowbridge HO, Emling RC. Inflammation: a review of the process. 2nd ed. Bristol, PA: Comsource Distribution Systems, 1983:16-37, 49-51, 76-80.
12. Zwifach BW. Vascular events in the inflammatory process. In: Zwifach BW, Grant L, McCluskey RT, eds. *The inflammatory process*. Vol 2, 2nd ed. New York: Academic Press, 1973:3-40.
13. Bainton DF. The cells of inflammation: a general view. In: Weissmann G, ed. *The cell biology of inflammation*. Vol 2. Amsterdam: Elsevier/North-Holland, 1980:1-25.
14. Sciubba JJ, Waterhouse JP, Meyer J. A fine structural comparison of the healing of incisional wounds of mucosa and skin. *J Oral Pathol* 1978;7:214-27.
15. McGrath MH, Emery JM. The effect of inhibition of angiogenesis in granulation tissue on wound healing and the fibroblast. *Ann Plast Surg* 1985;15:105-22.
16. Hunt TK, Andrews WS, Halliday B, et al. Coagulation and macrophage stimulation of angiogenesis and wound healing. In: Dineen P, Hildick-Smith G, eds. *The surgical wound*. Philadelphia: Lea & Febiger, 1981:1-18.
17. Ordman LN, Gillman T. Studies in the healing of cutaneous wounds. Part I. The healing of incisions through the skin of pigs. *Arch Surg* 1966;93:857-82.
18. Ordman LN, Gillman T. Studies of the healing of cutaneous wounds. Part II. The healing of epidermal, appendageal, and dermal injuries inflicted by suture material in the skin of pigs. *Arch Surg* 1966;93:883-910.
19. Folke LE. Revascularization in the oral mucous membrane following microvascular surgery. *Acta Odontol Scand* 1970;28:785-810.
20. Kline L, Weiss PH. Induced connective tissue metabolism in vivo: reutilization of pre-existing collagen. *Proc Natl Acad Sci USA* 1966;56:277-84.

You Might Be Interested to Know

It is reported that a physician was recently convicted of Medicare fraud. It seems that during a house call to an elderly patient he repaired a hole in her roof and then billed the procedure to Medicare. This engenders speculation as to the exact nature of his error. Did he perhaps bill for treatment of residential alopecia and thus was exposed for using the wrong DRG? With a bit of imagination, he could have billed for a preventive medicine category. After all, rain through the roof could cause dampness leading to URI's, arthritis, even athlete's foot . . . Where would it all end?

Upon conviction, the physician was fined and sentenced to 300 hours of community service. Repairing roofs???

Zachariah Yeomans