

CASE REPORT

Retrograde Instrumentation and Obturation with New Devices

Robert K. Flath, DDS, and M. Lamar Hicks, DDS, MS

Two surgical cases are presented in which retrograde instrumentation of the root canal was accomplished with sonic or ultrasonic instruments. The canals were obturated from a retrograde direction with thermoplasticized gutta-percha and root canal sealer. Success of these treatment approaches is attributed to thorough debridement and satisfactory obturation with equipment only recently available in the marketplace.

The goal of endodontics is to debride and obturate the root canal system. Although nonsurgical endodontic therapy routinely achieves a high success rate, endodontic surgery may be necessary when a nonsurgical approach is not possible or has failed. Endodontic surgery offers access to the periradicular area. The traditional surgical approach is to resect the root apex and place a retrofilling, especially when the adequacy of the existing root canal seal is uncertain. A problem arises when the traditional surgical approach leaves portions of the root canal system undebrided and unobturated in teeth where nonsurgical endodontic therapy is not possible. Because success in nonsurgical endodontics is based on the principles of thorough debridement and complete obturation of the root canal system, it is logical not to ignore or compromise these principles for teeth requiring endodontic surgery.

Recently, three instruments have been introduced to endodontic practitioners. The Cavi-Endo (Dentsply International Inc., York, PA) uses ultrasound energy to enhance debridement during mechanical instrumentation of the root canal (1). The Endostar 5 (Syntex Dental Products, Valley Forge, PA) incorporates sonic energy to aid canal debridement and preparation (2). The Obtura (Unitek Corp., Monrovia, CA) thermoplasticizes gutta-percha to facilitate obturation of the canal system (3).

Although these new instruments are commonly used in nonsurgical endodontic therapy, their use in surgical

endodontics has been sparsely reported. The purpose of this case report is to demonstrate the use of the Cavi-Endo, Endostar 5, and the Obtura for instrumentation and obturation of the root canal space from a retrograde direction during endodontic surgery.

CASE 1

A 65-yr-old male presented to the endodontic service with a chief complaint of "my upper molar hurts when I bite." Visual examination showed the maxillary right first molar with a large MODFL amalgam onlay restoration and a separate class V amalgam restoration on the palatal root. Although the tooth was tender to percussion, there were no signs of swelling or infection. The patient responded normally when the maxillary right first molar and first bicuspid were tested with an ice stick and an electric pulp tester. The maxillary right second bicuspid had been previously endodontically treated. A preoperative radiograph showed a radiolucency associated with the palatal root of the first molar (Fig. 1). The buccal canals appeared to be calcified. A clinical diagnosis of irreversible pulpitis with chronic

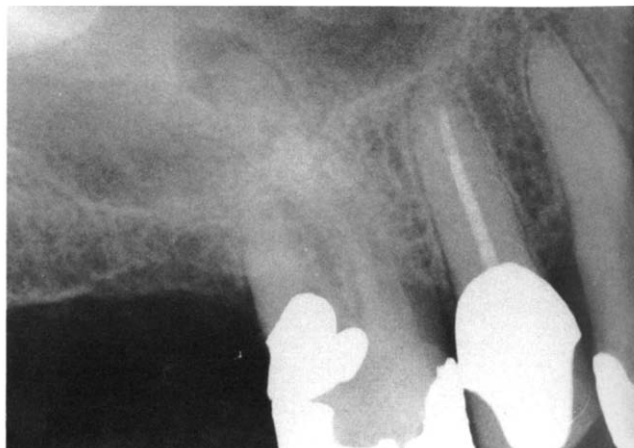


FIG 1. Case 1, preoperative radiograph. Note the radiolucency associated with the palatal root of the maxillary right first molar.

periradicular periodontitis was made for the first molar. Nonsurgical endodontic therapy was started. After administering local anesthesia and applying a rubber dam, access opening into the pulp chamber revealed necrotic tissue in the palatal canal and hemorrhagic tissue in the small distobuccal canal. The root canal system of the mesiobuccal root was not found. Canal preparation in the two patent canals was completed, the access opening temporarily sealed, and the patient appointed for continuation of therapy.

When the patient reported for his appointment 4 days later, he was asymptomatic. It was decided that continued searching for the mesiobuccal canal would increase the probability of a procedural accident occurring, thereby further jeopardizing the prognosis. The palatal and distobuccal canals were obturated with gutta-percha and Roth 801 sealer (Roth Drug Co., Chicago, IL) using lateral condensation (Fig. 2). The pulp chamber and the access opening were then filled with silver amalgam.

At a 6-month follow-up examination, the patient reported no spontaneous symptoms but did exhibit tenderness to palpation over the mesiobuccal root apex. Although the follow-up radiograph showed that the palatal lesion was healing, the mesiobuccal root now exhibited periradicular pathosis (Fig. 3).

Because the nonsurgical approach had been unsuccessful, the treatment plan now called for a surgical approach to the mesiobuccal root apex. After administering 3.6 ml of 0.5% Marcaine with 1:200,000 epinephrine (Breon Winthrop, New York, NY), a full-thickness mucoperiosteal flap with a mesial vertical releasing incision was reflected. The periradicular lesion had eroded the cortical plate. After gaining adequate access to the root apex by removing bone and curetting soft tissue, an apicoectomy that produced a long radicular bevel was accomplished. This procedure exposed the mesiobuccal root canal system. Before the surgery appointment, handles of a series of K files (Kerr, Romulus, MI) had been removed. With the shortened files

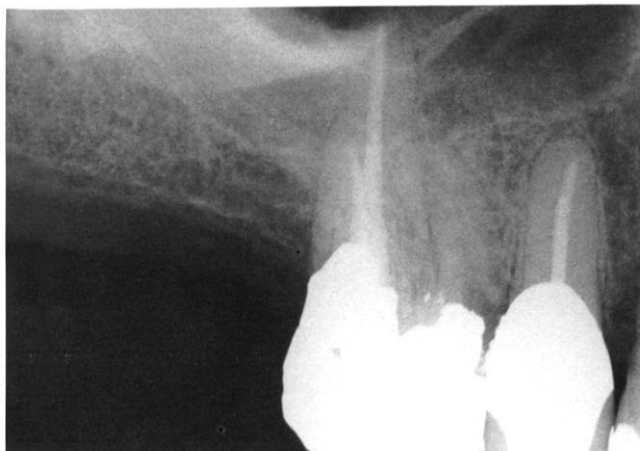


FIG 2. Radiograph shows obturation of palatal and distobuccal canals.

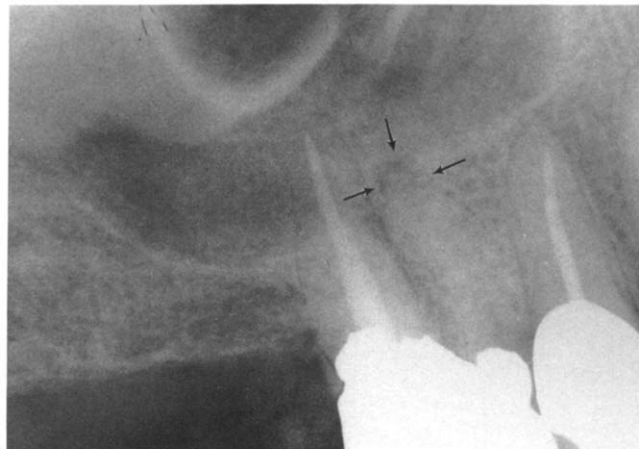


FIG 3. Six-month follow-up radiograph. Note the radiolucency associated with the mesiobuccal root (arrows) and the substantially reduced size of the radiolucency at the apex of the palatal root.

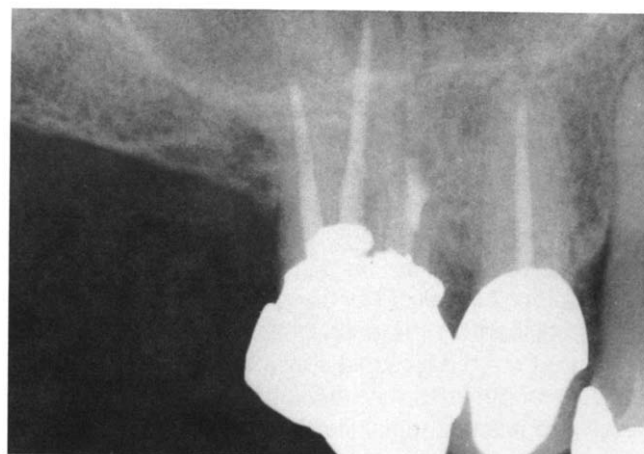

FIG 4. Immediate postoperative retrofilling radiograph.

held in hemostats, the canal system was enlarged to the size of a #15 K file to a depth of 5 to 6 mm. A pronounced curve similar in shape to a $\frac{3}{8}$ circle FS-2 suture needle (Ethicon, Inc., Somerville, NJ) was placed in a #15 Cavi-Endo file. Using sterile saline as an irrigant, the canal was enlarged with this instrument to approximately the size of a #25 K file. The root apex was isolated by packing the bony defect with sterile gauze. After drying the canal with paper points and applying root canal sealer, the canal was obturated with gutta-percha using the Obtura and vertical condensation (Fig. 4). The applicator tip of the Obtura was also curved for access purposes to match the curve of the file. The gauze was removed, the surgical site irrigated with sterile saline, and the flap repositioned and sutured. The postoperative course was uneventful.

At a follow-up examination 15 months after treatment, the patient was asymptomatic and the soft tissue morphology was normal. A recall radiograph showed a normal peripheral bone pattern and an intact periodontal ligament space surrounding the roots (Fig. 5).

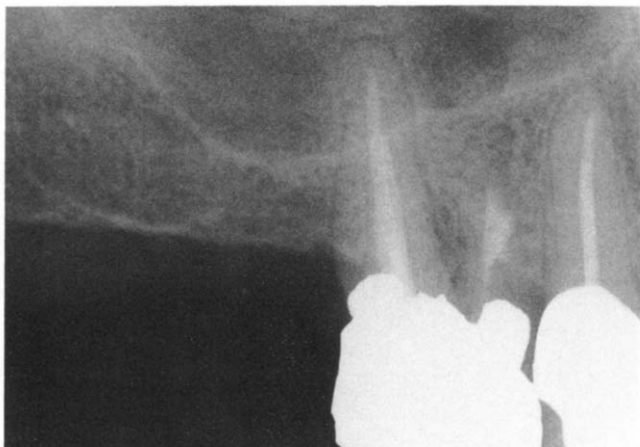

FIG 5. A 15-month recall radiograph shows restitution of normal structures around the mesiobuccal and palatal root apices.

CASE 2

A 42-yr-old male presented to the endodontic service with a chief complaint of "I noticed something different" in the maxillary left quadrant. He first noticed intermittent symptoms 3 wk previously. He described his symptoms as a throbbing, especially during exercise. He recalled having had root canal therapy in this area approximately 20 yr ago. Clinical examination revealed a maxillary left second bicuspid with a full gold crown restoration. A localized swelling was in the buccal vestibule adjacent to the apex of the second bicuspid. A radiograph of the bicuspid showed a post, an unobturated canal between the post and the root apex, and a large periradicular radiolucency (Fig. 6). Vitality tests of adjacent teeth were within normal limits. A diagnosis of a pulpless, endodontically untreated root canal and Phoenix abscess was made.

Endodontic surgery was selected as the treatment of choice because of the risk of fracturing the tooth during post removal and the patient's desire to retain the existing restoration.

After administering local anaesthesia, a full-thickness mucoperiosteal flap was reflected to gain access to the root apex. A soft tissue lesion was removed by curettage. Visual examination of the apex showed a dark discoloration at the apical foramen. An apicoectomy with a straight fissure bur provided a suitable bevel. The most apical portion of the canal was countersunk with a small round bur to facilitate access and intracanal instrumentation. For canal debridement, a #20 Endostar 5 file, followed by a #35 Endostar 5 file, was placed and worked in the canal to the level of the most apical portion of the post. The file was precurved to facilitate access into the canal. Tap water, delivered through an accessory filter attachment, was used for irrigation during instrumentation. The canal was enlarged to approximately a #50 K file within 3 min. The

root apex was isolated with bone wax (Ethicon, Inc.) to control hemorrhage. After final canal irrigation and drying and application of sealer, the canal was obturated with thermoplasticized gutta-percha using the Obtura. A gradual long bend in the applicator tip of the Obtura allowed easier access into the canal. Vertical condensation with a retrofilling amalgam plugger while the gutta-percha was pliable created close marginal adaptation of the filling. The bone wax was removed and the flap repositioned and sutured. The postoperative radiograph showed complete obturation of the root canal from the post to the apex (Fig. 7). Healing was uneventful and within normal limits. The patient reported no postoperative discomfort and did not require the analgesics that were prescribed.

Follow-up examination at 6 wk and 1 yr showed normal architecture of the soft tissues, and the tooth was nonmobile and asymptomatic. The recall radiograph at 1 yr showed excellent osseous regeneration and a normal periodontal ligament space (Fig. 8).

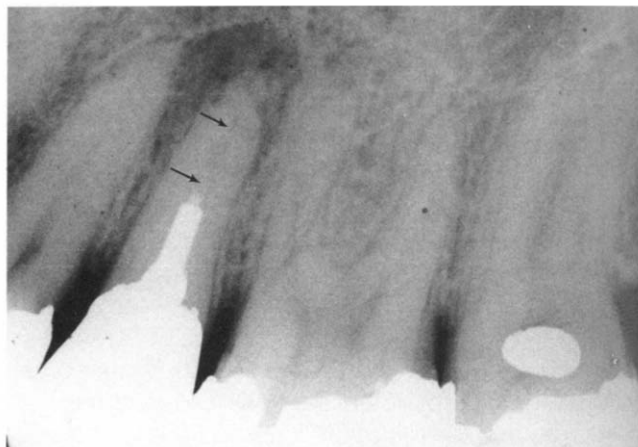


FIG 6. Case 2, preoperative radiograph. Note the unfilled canal space apical to the post (arrows) and the large periradicular radiolucency.

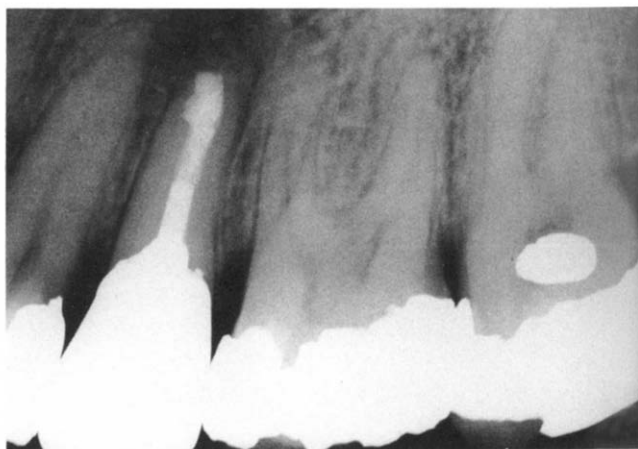

FIG 7. Immediate postsurgical radiograph. Note the gutta-percha material extending from the post to the root apex.

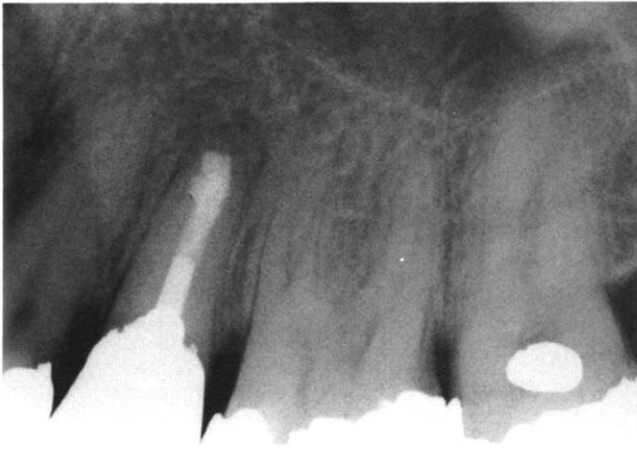

FIG 8. One-year recall radiograph. Note the osseous regeneration and normal periodontal ligament space.

DISCUSSION

In the two cases presented, three new endodontic devices designed for nonsurgical endodontic treatment worked well in the surgical treatment of each patient. The treatment was successful over the period of time that the patients were followed. Both debridement systems have inherent advantages and disadvantages. The Cavi-Endo offers a greater choice of irrigation through a reservoir within the unit, whereas the Endostar 5 is limited to filtered tap water. The Endostar 5 appeared to remove tooth structure more rapidly than the Cavi-Endo. In the second patient, creating a countersink with a round bur after the apicoectomy may have enhanced the impression that the Endostar 5 was more rapid cutting. The Endostar 5 can be disassembled and autoclaved. The Cavi-Endo requires disinfection and cold sterilization. In both systems, the files were curved to facilitate access to the apex and the apical portion of the root canal. The pronounced bend decreased the overall length of the file and allowed access from the buccal. Without the bend, straightline access would have been impossible with the equipment as it was designed for nonsurgical endodontic therapy. Although carefully designed studies that scientifically compare the two debridement and preparation systems are still needed, they are beyond the scope of this case report.

In both teeth, root canal sealer was used in conjunction with the thermoplasticized gutta-percha. ElDeeb (5) demonstrated that root canal sealer is required for satisfactory obturation with thermoplasticized gutta-percha. It is necessary because gutta-percha alone does not adhere to the walls of the canal.

No retrofill amalgam restorations were placed because visual and tactile inspection of the apex showed that the gutta-percha was closely adapted to the canal walls. Harrison and Todd (6) demonstrated that an apicoectomy with a rotary instrument in a high-speed handpiece does not disturb the seal of previously condensed gutta-percha and sealer. Although they questioned the routine use of retrofilling for establishing an apical seal, they did state that when doubt exists about the adequacy of obturation, a retrofilling should be placed. In the two cases presented, obturation succeeded apical resection. There was no doubt clinically that the gutta-percha/sealer filling was well-condensed and well-adapted marginally. Thus, an amalgam retrofilling was not considered to be necessary.

Today, the specialty practice of endodontics requires practitioners to acquire more technical skills and provide a wider variety of sophisticated clinical solutions. This case report demonstrates some of these additional skills and solutions. The successful results obtained in both cases are based on thorough debridement and satisfactory obturation with equipment only recently available in the marketplace.

We wish to express appreciation to all of the staff and residents of the Endodontics Department, Naval Dental School, Bethesda, MD, who assisted in the development of this case report.

The views expressed in this article are those of the authors and do not reflect the official policy or position of the Department of the Navy, Department of Defense, or the United States Government.

Commercial materials and equipment are identified in this report to specify clinical procedures. Such identification does not imply recommendation or endorsement or that the materials and equipment are necessarily the best available for the purpose. The authors have no commercial interest in the products mentioned.

Dr. Flath is a Commander, Dental Corps, United States Navy, and department head, Endodontics Department, Branch Dental Clinic, U.S. Naval Station, Rota, Spain. Dr. Hicks is a Captain, Dental Corps, United States Navy, and chairman, Endodontics Department, and director, Advanced Program in Endodontics, Naval Dental School, Bethesda, MD. Address requests for reprints to Captain M. L. Hicks, Endodontics Department, Naval Dental School, Naval Dental Clinic, NMCNCR, Bethesda, MD 20814-5077.

References

1. Cohen S, Burns RC (eds) Pathways of the pulp. St. Louis: CV Mosby, 1984:197-200.
2. Tronstad L, Barnett F, Schwartzben L, Frasca P Effectiveness and safety of a sonic vibratory endodontic instrument Endod Dent Traumatol 1985;1:69-76.
3. Marlin J, Krakow AA, Desilets RP, Gron P Clinical use of injection-molded thermoplasticized gutta-percha for obturation of the root canal system: a preliminary report J Endodon 1981;7:277-81.
4. Langeland K, Liao K (KS), Pascon EA. Work-saving devices in endodontics: Efficacy of sonic and ultrasonic techniques. J Endodon 1985;11:499-510.
5. ElDeeb ME The sealing ability of injection-molded thermoplasticized gutta-percha. J Endodon 1985;11:84-6.
6. Harrison JW, Todd MJ. The effect of root resection on the sealing property of root canal obturations. Oral Surg 1980;50:264-72.