

Comparison of Dentinal Crack Incidence and of Post Removal Time Resulting from Post Removal by Ultrasonic or Mechanical Force

Joel H. Altshul, DMD, Gordon Marshall, DMD, Leslie A. Morgan, DMD, and J. Craig Baumgartner, DDS, PhD

The purpose of this study was to compare the frequency of canal and intradentin cracks after intraradicular post removal using ultrasonic instrumentation or the Gonon post removal system. Sixty cadaver teeth were divided into 4 groups of 15 teeth each: group 1, ultrasonic removal; group 2, Gonon post removal system; group 3, cemented posts not removed; and group 4, no posts. Groups 1 and 2 were contralateral matched pairs. Para Posts were placed in groups 1, 2, and 3 to 7 mm apical to the cementsoenamel junction and luted with ZnPO₄ cement. The time required for post removal in groups 1 and 2 was recorded. The teeth were extracted, sectioned, and examined. Canal and intradentin cracks were mapped, and their frequency was recorded at each level. There were statistically more cracks present in the ultrasonic group than the no post group. There were no other differences that reached statistical significance. It took significantly longer for post removal using the ultrasonic tip versus the Gonon system.

Patients often require nonsurgical endodontic retreatment of teeth with cemented intraradicular posts. To allow successful retreatment, these posts must be removed atraumatically to prevent cracking or vertically fracturing the root, which might necessitate tooth extraction.

There have been many techniques developed to facilitate removal of posts from the root canal space. Some authors advocate the use of trephine burs and extractors (1), whereas others have suggested the use of ultrasonic devices to remove posts (2).

Posts can be removed ultrasonically by removing the coronal luting agent with an ultrasonic instrument and then using the tip of an ultrasonic instrument to vibrate the metal post until it loosens. Ultrasonic energy is imparted to the metal post until the cement fails and the loosened post is removed (2). This method of post removal may be advantageous because very little tooth structure is removed (3).

The safety of this procedure, however, has not been shown. Ultrasonic root-end preparation has been shown to increase significantly the frequency of incomplete dentinal fractures (4, 5). It has been postulated that incomplete fractures may, with time, lead to vertical root fractures (6, 7). It is possible that the use of ultrasonic energy for post removal may lead to root cracking or vertical fractures.

The purpose of this study was to compare the frequency of root cracks produced after post removal using either ultrasonic energy or the Gonon post removal system, and the length of time required for post removal using the two techniques.

MATERIALS AND METHODS

Fifteen matched pairs of teeth in cadavers and 32 unmatched cadaver teeth from 10 sagittally split cadaver heads were used in this study to duplicate closely the in vivo condition. Sixty of these teeth were used in four experimental groups. Two cadaver and two freshly extracted teeth stored in phosphate-buffered saline with 0.2% sodium azide (PBS) were used in a control experiment. Teeth used were limited to maxillary and mandibular incisors and premolars. The bilaterally matched teeth were randomly divided into two experimental groups of 15 teeth each, as were the nonmatched teeth groups. Pretreatment radiographs were taken, and the crowns were removed at the cementsoenamel junction (CEJ) perpendicular to the long axis of the teeth using a high-speed #557 fissure bur.

All 60 experimental teeth were instrumented using a crown-down step-back technique (8) to at least file size 30 (Union Broach, Emigsville, PA) or two file sizes larger than the first file to bind 1 mm short of the radiographic apex (9). Canals were irrigated with 2 ml of 5.25% NaOCl (Master X, Portland, OR) after every other file and after final preparation. The canals were dried with paper points and obturated with laterally compacted gutta-percha using Roth's 801 root canal sealer (Roth International, Chicago, IL) using a fine finger spreader. Group 4 received no further treatment.

Forty-seven cadaver teeth and two freshly extracted teeth had #4 Para Posts (Coltene/Whaledent, Mahwah, NJ), placed using a modification of the technique of Goldman et al. (10). A 7 mm post space was created with a Para Post #3 drill and enlarged with the #4 drill. At least 4 mm of apical gutta-percha remained in the canals after preparation. The preparation was irrigated with 1 ml of

15% EDTA (Sigma Chemical Co., St Louis, MO), followed by 1 ml of 5.25% NaOCl and dried with paper points.

Posts to be removed using the ultrasonic tip were cut to a length of 11 mm, and a keyway was placed into the coronal portion of the post with a #701 bur. This was done to facilitate the eventual attachment of a loop of fishing line (3). The posts that were removed with the Gonan post remover (Thomas extracteur de pivots, FFDM-Pneumat, Bourge, France) were prepared by cutting off the flattened end of the Para Post, leaving 11 mm of post remaining. There was 4 mm of post extruding coronally from each tooth.

Posts were checked for close adaptation to the canal walls to ensure that the post spaces were not overflared. Zinc phosphate cement (Mizzy, Cherry Hill, NJ) was mixed according to the manufacturer's specifications and placed into the post space using a #45 stainless-steel K-file (Brasseler, Savannah, GA). The apical 7 mm of the post was coated with cement, and it was seated into the preparation. Seating of the post was verified with a ruler, and it was stabilized with light finger pressure until initial cement setting. The cadaver heads were stored in air-tight plastic containers for at least 1 wk to allow complete setting of the cement.

Blunt dissection was used to remove the tissue overlying the buccal and lingual surfaces of the alveolar bone. The jaws were held stationary using a "C" clamp to simulate the muscles of mastication holding the jaw firmly against resistance. Group 1 had the posts removed by modification of the method of Buoncrisiani et al. (3). Constant tension was applied to the post from a 1 kg weight suspended from a pulley and attached with a fishing line to the keyhole in the post. The force was maintained directly along the long axis of the post. An ultrasonic TFI #25 tip in a BOBCAT ultrasonic unit set on high power (Dentsply Equipment, Long Island City, NY) was applied to the post using constant water spray at a level 2 mm above the coronal surface of the tooth. The position of the tip was moved clockwise 360 degrees around the post at this level to induce harmonics. At no time did the ultrasonic tip touch tooth structure.

Group 2 had their posts removed using the Gonan post removal technique, as described by Sakkal et al. (1). A #2 trephine bur in a low-speed handpiece was placed over the post, being careful not to touch tooth structure. This allowed proper adaptation of the #2 mandrel onto the post. One silicone and two metal rings were placed onto the shank of a #2 mandrel, as recommended by the manufacturer to act as a cushion to prevent root fracture and allow an even distribution of forces during post extraction. The #2 mandrel was then screwed over the post and rotated clockwise until fully engaged. The post puller was then applied and the post extracted.

The length of time necessary to remove each post was recorded using a stop watch.

In group 3, the posts were left intact and those teeth received no further treatment.

Four teeth were tested for post retentiveness in cadaver versus freshly extracted teeth. Teeth and posts were prepared as per group 3; two maxillary canines in cadavers and two freshly extracted human canine teeth stored in PBS. The teeth were placed into an Instron testing machine (Instron Engineering Corp., Canton, MA), and the posts were removed along the long axis. The force necessary to dislodge the posts was recorded.

The cadaver teeth were removed in block section using a Lindeman bone bur (Brasseler, Savannah, GA). Overlying bone was removed using a side-cutting Rongeur. The teeth were placed in covered 20 ml scintillation vials (Wheaton, Millville, NJ) filled

TABLE 1. Cracks at different section levels

Group	Section Level (mm)	Canal Cracks		Intradentin Cracks
		Complete	Incomplete	
1	0	9	14	11
	4	1	7	2
	7	1	9	3
	10	0	10	4
2	0	6	3	3
	4	1	7	0
	7	0	2	0
	10	0	2	3
3	0	10	2	1
	4	0	4	0
	7	2	1	1
	10	2	6	0
4	0	2	6	3
	4	0	1	0
	7	0	5	2
	10	0	0	3

Group 1 = ultrasonic post removal; group 2 = Gonan post removal system; group 3 = endodontic treatment and post; and group 4 = endodontic treatment only.

with PBS. The experimental vials were coded to allow for blinded evaluation. The teeth were sectioned at 4, 7, and 10 mm from the CEJ perpendicular to the long axis of the root using a low-speed diamond wafering saw (4 inches \times 0.012 inches) (Isomet; Buehler Ltd., Lake Bluff, IL) with continuous water lubrication. The four sections were immediately replaced into the scintillation vials and stored with a new solution of 0.004% aqueous methylene blue dye (Roth International) adjusted to pH 7.0 (11). Forty-eight hours after immersion, two independent examiners using the methods of Layton et al. (5) examined and mapped the sections using a zoom stereomicroscope (Nikon SMZ-2T, Melville, NY) ($\times 20$ to $\times 63$) with a fiberoptic transilluminating light source (Quality Aspirators, Duncanville, TX) held at least one-half inch from the root surface. A timer was used to ensure that the observation time for each section did not exceed 2 min. The presence and location of cracks on the coronal surface of the root sections were mapped. Disagreements between the two evaluators were discussed and a consensus reached.

Differences in the numbers and types of cracks observed after root sectioning between different groups were statistically analyzed using a three-way ANOVA (Groups \times Crack Type \times Depth). Scheffé tests were used for individual comparisons within each mean effect. The significance level was set at $p = 0.05$.

RESULTS

Results were obtained from 57 teeth. Three specimens were lost during removal of the teeth from the cadavers, two in group 2 and one in group 3.

Results are shown in Table 1. Two different types of cracks were observed on the root sections: canal cracks and intradentin cracks. Canal cracks were those cracks that originated within the canal and radiated into the dentin. Canal cracks were subdivided into complete and incomplete canal cracks. Complete canal cracks extended from the canal space to the external root surface (Fig. 1). Incomplete canal cracks extended from the canal space for a

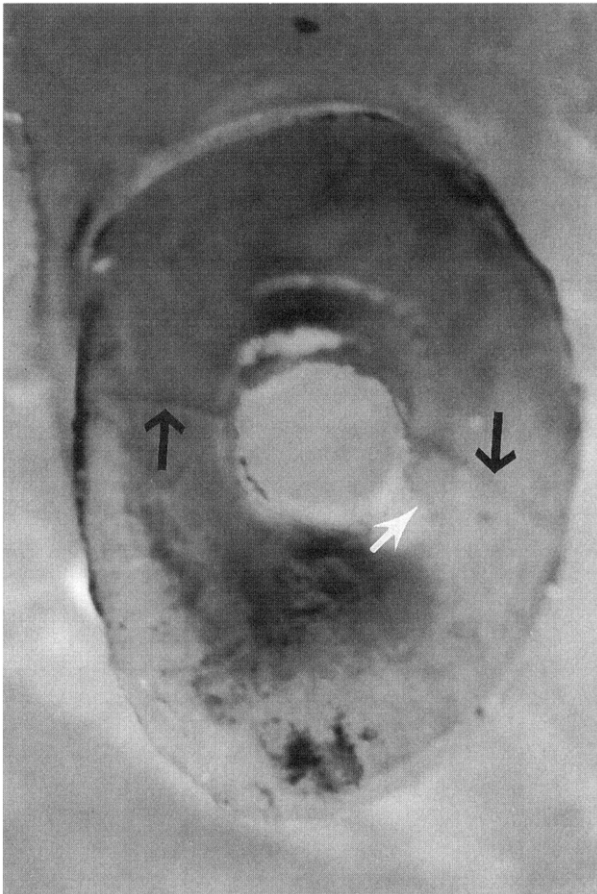


FIG 1. Mandibular lateral incisor group 2 (Gonan post removal) sectioned at CEJ (0 mm level) showing two complete canal cracks (black arrows) and one incomplete canal crack (white arrow). Original magnification $\times 20$.

variable distance into the dentin, but ended short of the external root surface (Fig. 1). Intradentin cracks were confined to dentin and tended to run in a faciolingual direction either mesial or distal to the canal (Fig. 2). Many of the sections in both the experimental and control groups had no visible cracks of any kind.

When comparing differences in total number of cracks present between the different groups, group 1 had significantly more cracks (complete, incomplete, and intradentin) than group 4 ($p = 0.0143$ (ANOVA), $p = 0.0266$ (Scheffé)). When comparing the total incidence of the different types of cracks, there were significantly more incomplete canal cracks than intradentin or complete canal cracks ($p = 0.0083$, ANOVA). When comparing the total number of cracks present at each level, there were significantly more cracks at the CEJ level (the level where the post emerged from the root) than at the other levels ($p = 0.001$, ANOVA). There were no other statistically significant results.

Instron tests on the two teeth from the cadavers had a mean post dislodgement force of 22.7 kg, whereas the two freshly extracted teeth with posts required a mean of 27.9 kg. Failure of the post was within the $ZnPO_4$ cement for all specimens.

The mean time necessary to remove posts with the Gonan post remover was 2.3 ± 0.9 min. The mean time necessary to remove posts using ultrasonic vibration was 7.7 ± 4.9 min. The time difference was statistically significant ($p = 0.0002$, ANOVA).

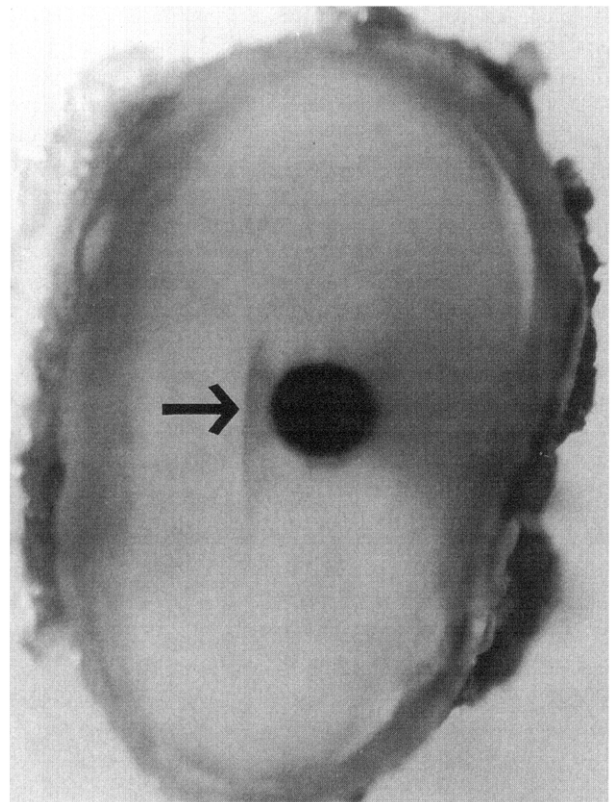


FIG 2. Mandibular canine group 4 (gutta-percha, no post placed) sectioned at the 7 mm level showing one intradentin crack (black arrow). Original magnification $\times 20$.

DISCUSSION

Cadavers were chosen for use in this study because of the biological effect the attachment apparatus exerts in supporting tooth structures during force application by either the ultrasonic or the Gonan remover.

Investigations studying incomplete dentinal fractures resulting from post removal must take into account that some incomplete dentinal fractures may also result from crown resection, endodontic preparation (12), tooth removal, tooth sectioning, or post placement (13). Some cracks observed may be inherent in the root and not the result of any preparation of the root canal system.

Onnink et al. (12) demonstrated cracks in instrumented and uninstrumented extracted teeth. They also showed obturation can produce intradentin and incomplete cracks (12). In vitro studies on the incidence of incomplete fractures in roots with posts have shown there is no greater likelihood of post placement causing root fracture than conventional endodontic therapy alone (13). Our results support these studies. However, this study showed there were significantly more cracks seen in teeth that had posts removed using ultrasonic energy compared with root canal-treated teeth with no posts. There were no significant differences in the numbers or types of cracks at any level when comparing group 1 (ultrasonic) versus group 2 (Gonan).

Crowns were removed from the teeth while still in the cadaver heads. A fissure bur was used in a high-speed handpiece that could have produced cracks in the roots at the CEJ level. Because identical techniques were used on all teeth, and groups were randomly selected after all root canal preparation and obturation

was completed, the frequency of cracks introduced by the high-speed sectioning of the crowns should be the same in all groups.

Buonocristiani et al. (3) showed a mean post dislodgement force of 33.5 kg when using Instron testing. Instron tests showed a mean post dislodgement force of 27.9 kg in noncadaver teeth and a mean post dislodgement force of 22.7 kg in cadaver teeth. The difference between our results on noncadaver teeth and Buonocristiani's group (3) may be due to slight differences in technique, the size of the Para Post used, and depth of post placement. The 5.2 kg reduction in mean post dislodgement force in the cadaver teeth may be due to the effect of the phenol-alcohol cadaver preservative on the ZnPO₄ cement. The reduction in mean post dislodgement force seen with the cadaver teeth might suggest a decreased potential for root cracking with post removal from cadaver teeth over extracted teeth. It is unknown how this would compare with post removal in vivo. Visual inspection of the posts after removal from the cadavers revealed that failure occurred within the cement. Buonocristiani et al. also saw this cohesive type of failure in many of their specimens (3). Buonocristiani et al. (3) saw some failure occur at the cement-tooth interface. This type of failure was not seen in this study.

The incidence of dentinal cracks decreased gradually from groups 1 to 4, and this was why a significant difference in crack incidence was seen between group 1 and group 4, but not between any other groups. Although there was no difference in crack incidence between the ultrasonic and Gonan groups, there was a significant increase in the length of time it took to remove posts using ultrasonic energy versus the mechanical Gonan system.

Intradentin and canal cracks occurred in all groups. It seems that complete cracks rarely if ever extended for the entire root length. It can be speculated that, if the teeth were sectioned in a different plane, the incomplete canal cracks seen might be complete cracks.

This study showed that ultrasonic vibration of posts during removal caused significantly more cracks in the root at the surface or CEJ level compared with nonposted endodontically treated teeth. The potential for production of vertical root fractures may be

increased. In addition, post removal using the ultrasonic tip took significantly longer than the Gonan system.

We thank Dr. Dave Philips for his invaluable help with the statistical analysis.

Dr. Altshul is a former endodontic postgraduate student, Oregon Health Sciences University, School of Dentistry, Portland, OR, and is currently in private practice in San Diego, CA. Dr. Marshall is associate professor, Dr. Morgan is assistant professor, and Dr. Baumgartner is professor and chairman, Department of Endodontology, Oregon Health Sciences University, School of Dentistry, Portland, OR. Address requests for reprints to Dr. Gordon Marshall, Department of Endodontology, Oregon Health Sciences University, School of Dentistry, 611 S.W. Campus Drive, Portland, OR 97201.

References

1. Sakkal S, Gauthier G, Milot P, Lemian L. A clinical appraisal of the Gonan post-pulling system. *J Can Dent Assoc* 1994;60:537-42.
2. Gaffney JL, Lehman JW, Miles MJ. Expanded use of the ultrasonic scaler. *J Endodon* 1981;7:228-9.
3. Buonocristiani J, Seto BG, Caputo AA. Evaluation of ultrasonic and sonic instruments for intraradicular post removal. *J Endodon* 1994;20:486-9.
4. Saunders WP, Saunders EM, Gutmann JL. Ultrasonic root-end preparation. Part 2. Microleakage of EBA root-end fillings. *Int Endod J* 1994;27:325-9.
5. Layton CA, Marshall JG, Morgan LA, Baumgartner JC. Evaluation of cracks associated with ultrasonic root-end preparation. *J Endodon* 1996;22:157-60.
6. Walton RE, Michelich RJ, Smith GN. The histopathogenesis of vertical root fractures. *J Endodon* 1984;10:48-56.
7. Dang DA, Walton RE. Vertical root fracture and root distortion: effect of spreader design. *J Endodon* 1989;15:294-301.
8. Beling KL, Marshall JG, Morgan LA, Baumgartner JC. Evaluation for cracks associated with ultrasonic root-end preparation of gutta-percha filled canals. *J Endodon* (in press).
9. Grossman LI. *Endodontic practice*. 10th ed. Philadelphia: Lea and Febiger, 1981:207.
10. Goldman M, DeVitre, Pier M. Effect of the dentin smeared layer on tensile strength of cemented posts. *J Prosthet Dent* 1984;52:485-8.
11. Cambruzzi JV, Marshall FJ, Pappin JB. Methylene blue dye: an aid to endodontic surgery. *J Endodon* 1985;11:311-4.
12. Onnink PA, Davis RD, Wayman BE. An in-vitro comparison of incomplete root fractures associated with three obturation techniques. *J Endodon* 1994;20:32-7.
13. Boyarsky H, Davis R. Root fracture with dentin-retained posts. *Am J Dent* 1992;5:11-4.