

A study of endodontically apexified teeth

Kleier DJ, Barr ES. A study of endodontically apexified teeth. *Endod Dent Traumatol* 1991; 7: 112–117.

Abstract – This study was undertaken to determine the clinical and radiographic success of calcium hydroxide apexification in a group of 48 patients requiring endodontic therapy because of pulpal necrosis prior to root-end closure. The study examined tooth number, etiology of pulpal necrosis, age, sex, size of root-end opening, size of radiolucency, crown discoloration, interappointment symptoms, and total treatment time from initial instrumentation to completion of apexification. Apexification required an average of 1 year \pm 7 months. A statistically significant relationship was found between: the presence of a radiolucency and development of interappointment symptoms ($p < 0.04$); and the size of apex opening and development of interappointment symptoms ($p < 0.02$). If symptoms did develop, apexification was delayed an additional 5 months when compared to patients who did not have symptoms. Calcium hydroxide apexification was found to be statistically highly successful regardless of the clinical variables encountered.

Non-vital permanent teeth with immature root apices present a unique endodontic challenge. Current endodontic therapy requires that instrumentation of a root canal provide an apical stop or seat against which an endodontic filling material can be condensed. Teeth with immature apices that require endodontic therapy usually cannot be instrumented to provide such a stop (1).

Frank (2) popularized the use of calcium hydroxide powder and pastes to facilitate growth of an apical hard tissue barrier against which an endodontic filling material could be condensed. This barrier has been described as an osteoid or cementoid material that is firmly attached to the apical cementum and dentin of the immature root (3–5). The probable mechanism by which calcium hydroxide stimulates closure of an immature root apex has been described by Heithersay (6). The basic pH of calcium hydroxide and its physical presence within the root canal space is thought to provide a potent antibacterial effect, prevent ingress of granulation tissue, and inhibit osteoclastic activity. These characteristics encourage formation of hard tissue at the root apex (7–8). This technique, termed calcium hydroxide apexification, has been reported in the literature since the 1960's (9,10). Published case reports and several long term studies have stated a success rate of 74–96% (11–13). These studies evaluated closure of the root apex but did not inves-

tigate the effect of other clinical variables. One study attempted to correlate apical diameter to closure time (13).

This study was undertaken to determine the clinical and radiographic success of calcium hydroxide apexification in a group of patients requiring endodontic therapy because of pulpal necrosis prior to root-end closure; to determine if closure time could be predicted or correlated to other clinical variables; and to describe complications occurring during treatment and analyze their effect on the closure time and overall success.

Material and methods

The participants of this study were patients in the dental practices of the authors. Forty-one patients who had received calcium hydroxide apexification during the time period of 1978–1989 were included. The diagnosis of pulpal necrosis prior to root-end closure was established by a dental history, clinical examination including pulp testing, and periapical radiographs (Fig. 1). The apexification technique used by the authors consisted of a standard endodontic access, instrumentation to within one mm of the radiographic open apex using standardized k-type files, irrigation with 2.6% sodium hypochlorite, and placement into the canal space of either calcium hydroxide/camphorated parachlorophenol U.S.P.

Donald J. Kleier, Elizabeth S. Barr

University of Colorado, School of Dentistry, Denver, USA

Key words: endodontics; calcium hydroxide; root apex; dental injuries.

Donald J. Kleier, University of Colorado, School of Dentistry, Box C-284, 4200 E. 9th Ave., Denver, Colorado, USA 80262.

Accepted for publication December 2, 1990.

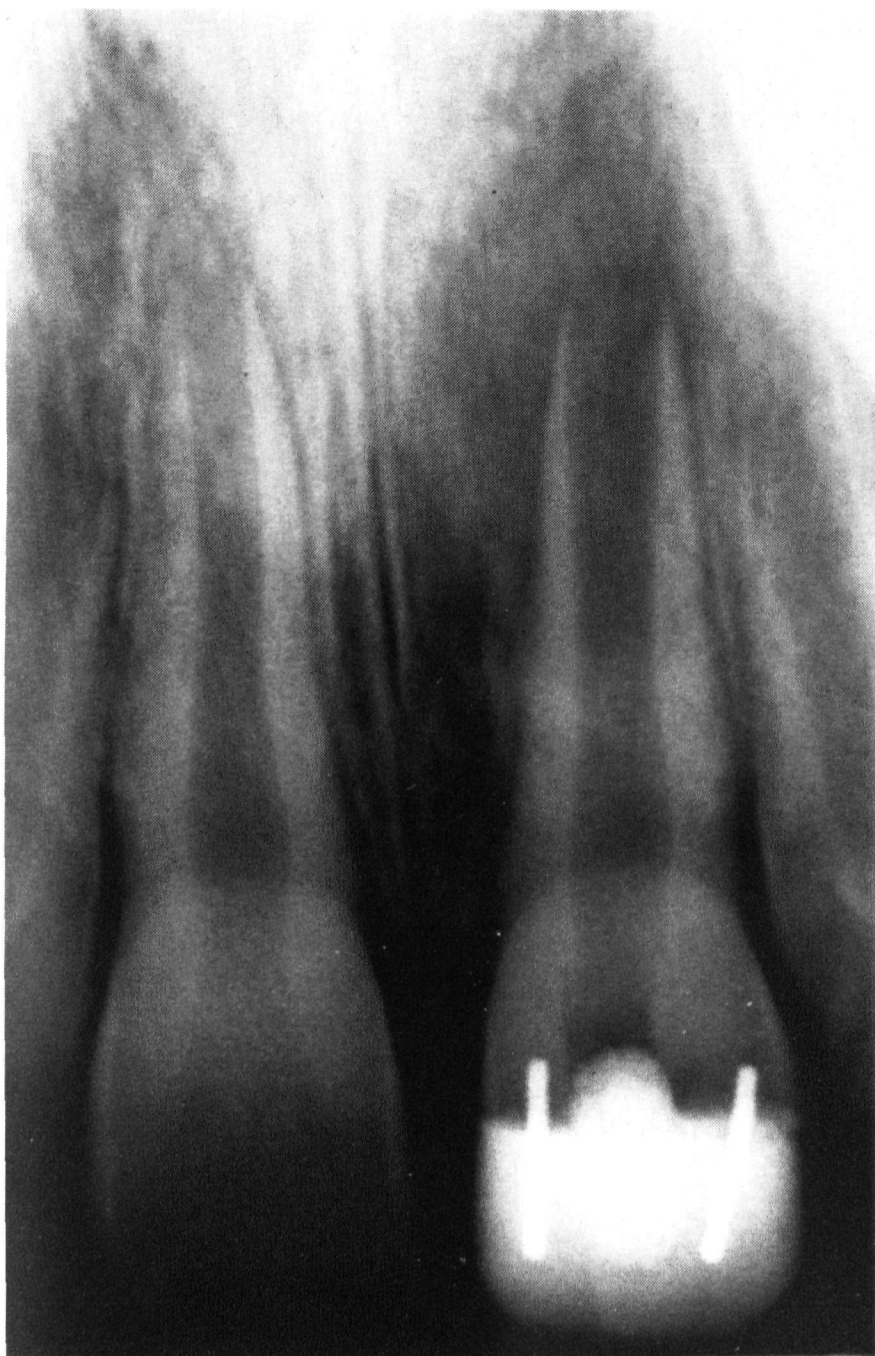

Fig. 1. Representative anterior tooth (#9) with an open apex and associated periapical radiolucency.

paste or calcium hydroxide in an aqueous methylcellulose base (Pulpdent, Brookline, MA, USA). The calcium hydroxide was placed upon completion of the initial instrumentation appointment (Fig. 2). Placement of the calcium hydroxide within the canal space was accomplished by packing the material with large files or pluggers or in some cases by using rotary compaction devices (14). The teeth were temporized between appointments.

The calcium hydroxide was replaced every 3 to 6 months as a routine until the apex was closed. Root-end closure was determined by gently probing beyond the established working length with an endodontic file several sizes smaller than the largest file used during instrumentation. Closure was determined to be complete when the probing file would not penetrate into the periapical tissue (Fig. 3). The root canal was then obturated with gutta-percha and an endodontic sealer using either lateral or vertical condensation (Fig. 4). If a radiolucency persisted at the time of obturation, the patient was recalled to verify reduction or healing of the radio-

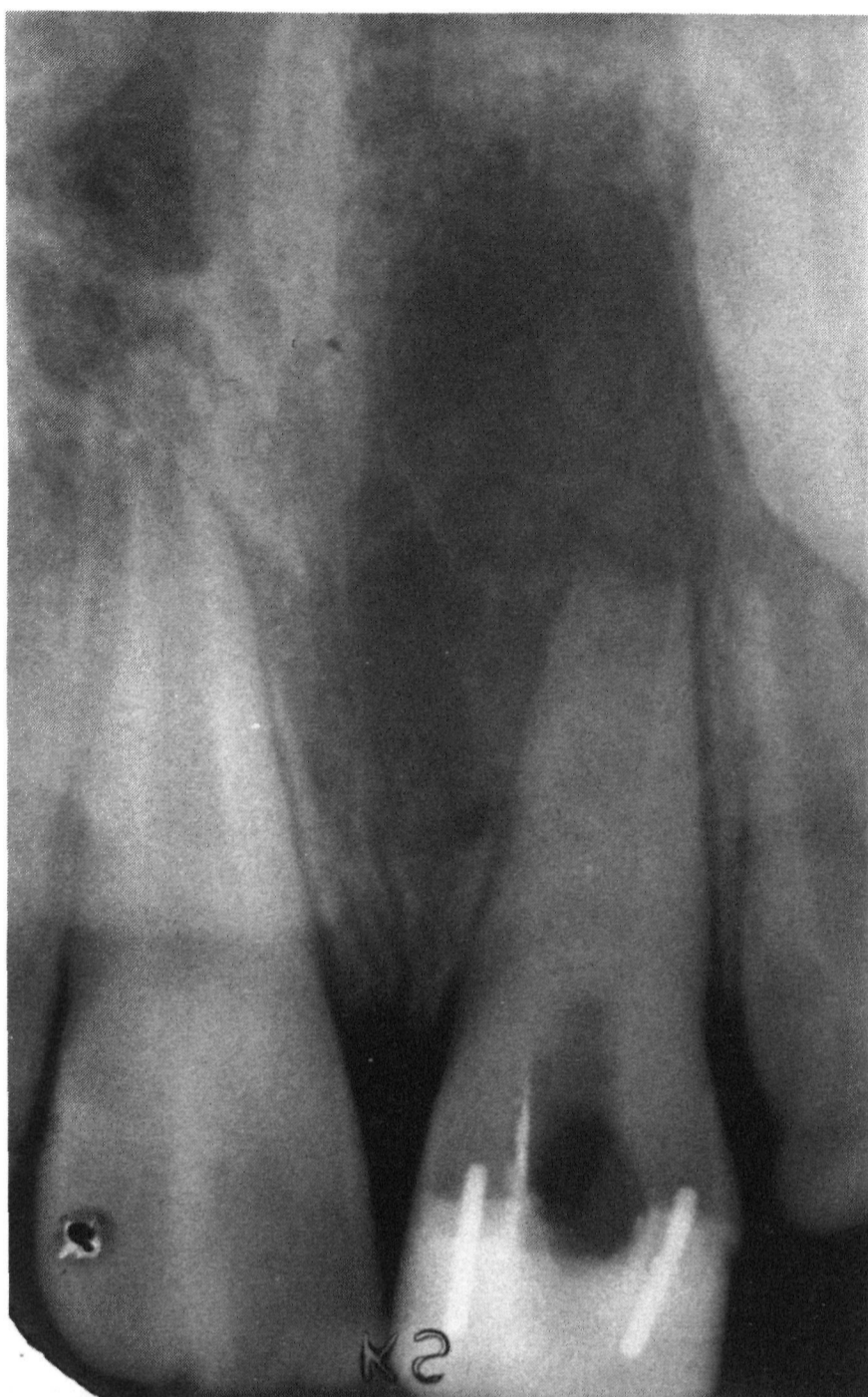

Fig. 2. Same case as in Fig. 1 showing canal filled with calcium hydroxide paste.

lucent lesion (Fig. 5). A long-cone parallel technique was used for all radiographic exposures but individualized film holders were not fabricated.

The clinical variables studied were tooth number, etiology of pulpal necrosis, age, sex, size of root-end opening, presence or absence of a radiolucency, crown discoloration, interappointment symptoms and total treatment time from initial instrumentation to completion of apexification. The root-end opening and size of radiolucency were measured by the authors from preoperative radiographs using a Boley gauge. The greatest width of the root canal opening at the apex was recorded. If a radiolucency were present, it was measured as its largest mesial-distal diameter.

Results

The 41 patients in this study yielded 48 teeth that required treatment. Forty-one of these teeth were incisors and 7 were molars. Of the 41 incisors

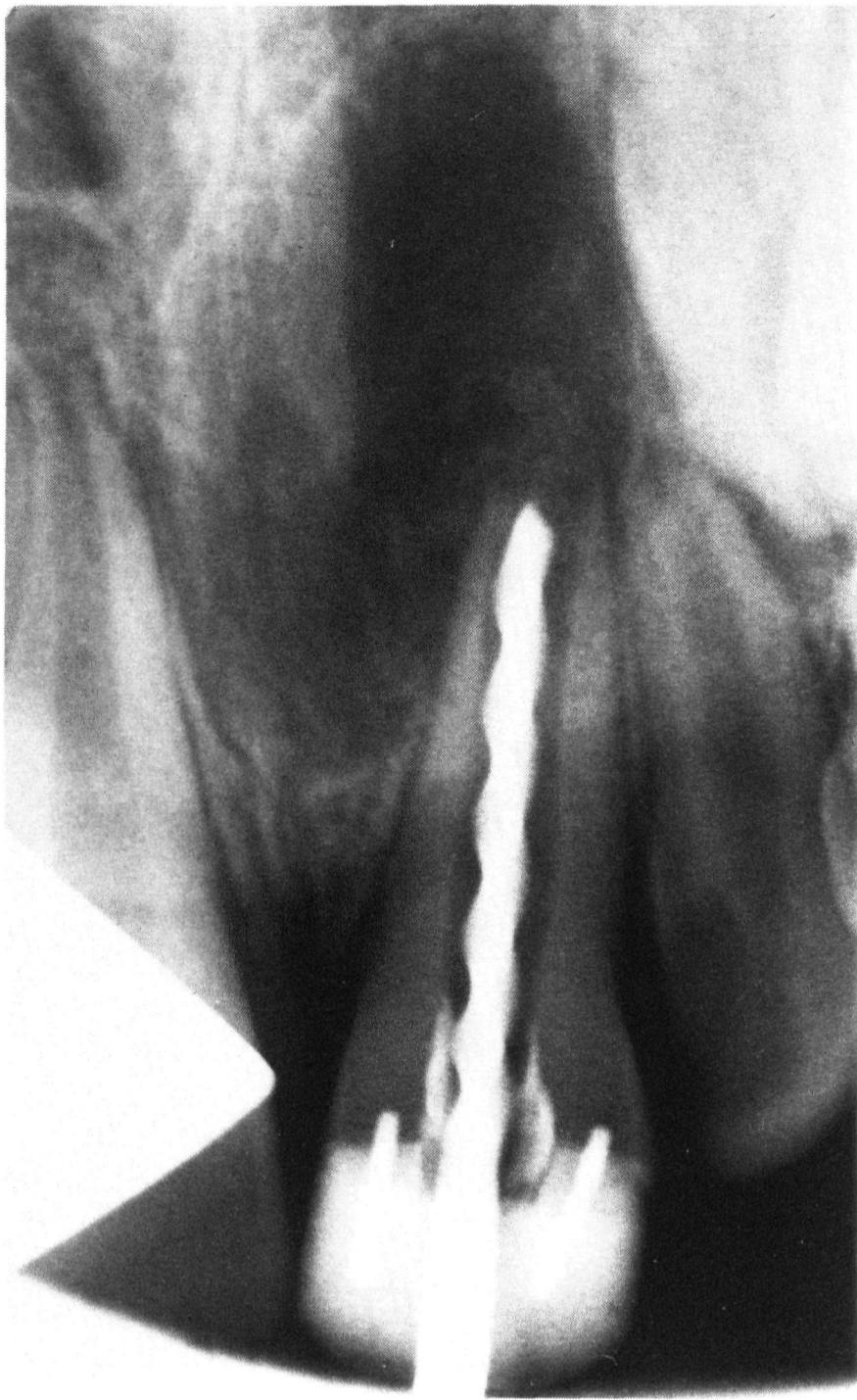

Fig. 3. Same case as in Fig. 1 showing an endodontic file probing the apical barrier.

treated, 16 became discolored and required endodontic bleaching after completion of apexification. There were 19 females and 29 males. Sex difference had no effect on the clinical variables studied. Trauma was responsible for pulpal necrosis in all the incisor teeth in both sexes with the exception of one lateral incisor that became necrotic because of a dens in dente malformation. All of the molar teeth required treatment because of caries. Twenty-six teeth had an associated radiolucency. Nine patients developed painful interappointment symptoms during treatment that required an unplanned office visit. All cases eventually formed an apical hard tissue barrier allowing completion of endodontic therapy and no case required periapical surgery or extraction. Table 1 shows other descriptive data for the patients in this study.

Table 2 compares 4 clinical variables found in patients who developed painful interappointment symptoms to those who did not develop symptoms. Statistically significant differences existed between

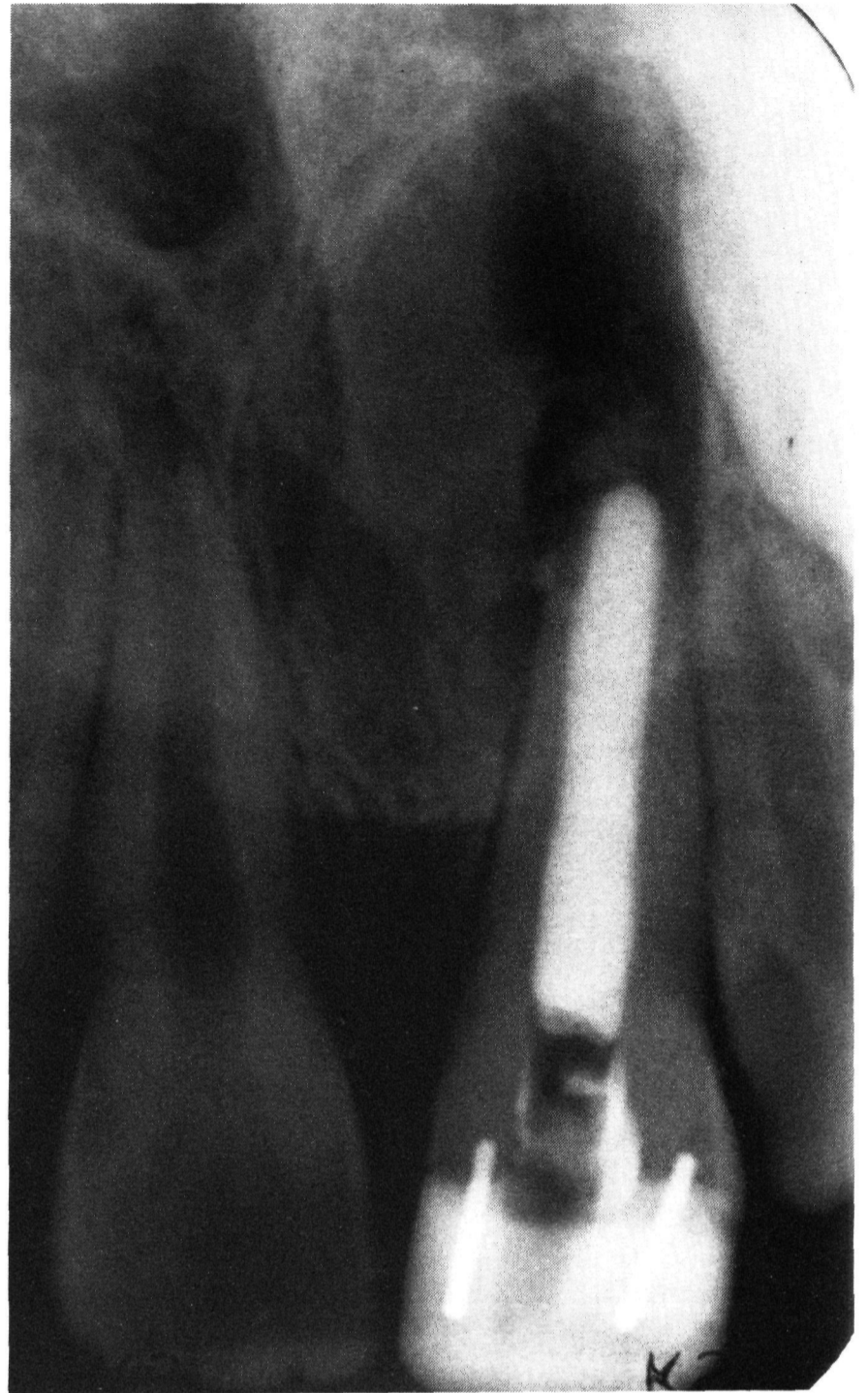

Fig. 4. Same case as in Fig. 1 showing postobturation radiograph. The canal was filled with vertically condensed warmed gutta-percha. The radiolucent lesion has not resolved but an apical barrier has formed.

the 2 groups when examining the length of closure time necessary for apexification, the size of apex opening, and if present, the size of an apical radiolucency.

Table 3 shows correlation coefficients for 4 clinical variables. When patients who had an apical radiolucency were grouped, a statistically positive correlation existed between the size of radiolucency and the size of apex opening.

Twenty patients who presented with an initial apical radiolucency had complete resolution of the apical lesion by the time the canal was obturated. The remaining six patients developed an apical barrier allowing canal obturation but had not yet achieved complete resolution of the apical lesion. Of these six patients, four eventually healed and two could not be recalled.

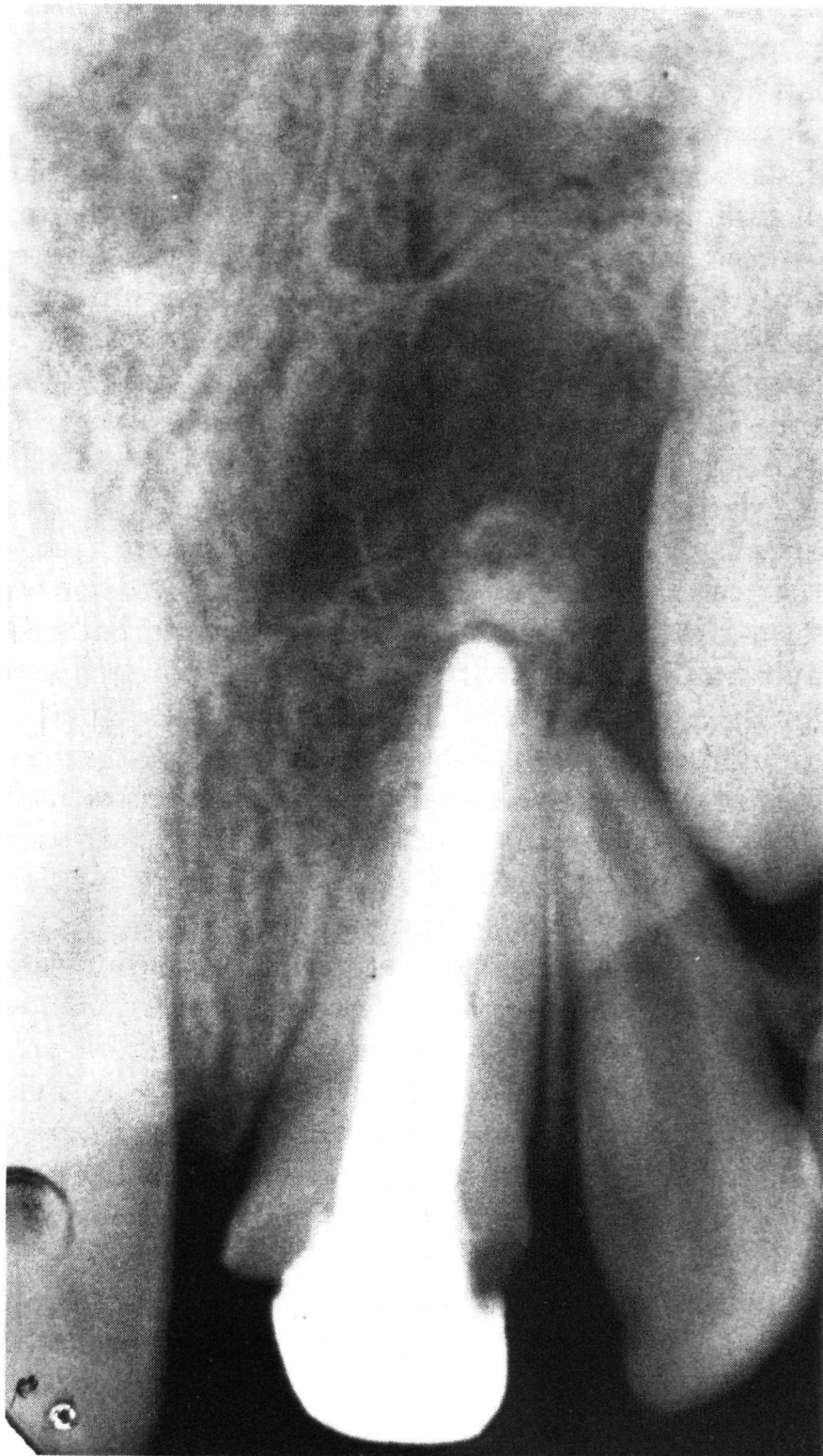


Fig. 5. Same case as in Fig. 1 showing 21-month recall radiograph. Significant apical bone regeneration has occurred.

Discussion

This study agreed with reports by Andreasen (15) that the most common teeth involved in trauma are the maxillary anterior teeth in juvenile males. In this study male patients outnumbered female patients by a factor of three. The major finding of this clinical study, however, was that the calcium

Table 1. Descriptive data for patients studied

Variable	Mean	S.D.	Range
Closure Time (mo)	11.6	7.6	1-30
Apex Opening (mm)	0.9	0.5	0.2-2.2
Radiolucency (mm)*	4.2	2.2	1.5-9.2
Age	10.2	1.8	7-15

* Represents only the 26 cases with a radiolucency.

Table 2. Comparison of variables for patients with vs. without symptoms

Variable	Average for patients with symptoms (n=9)	Average for patients without symptoms (n=39)	t	sig.
Closure time (mo)	15.9	10.6	1.96	0.05
Apex Opening (mm)	1.2	0.8	2.36	0.02
Radiolucency (mm)*	5.9	3.7	2.13	0.04
Age	10.7	10.1	0.86	n.s.

* Represents only the 26 cases with a radiolucency. Of the 26; 5 had symptoms and 21 did not.

hydroxide apexification technique was statistically highly successful. Apexification was defined as the development of an apical hard tissue barrier that allowed completion of nonsurgical endodontic therapy. This finding agreed with other studies that reported a high rate of clinical success for calcium hydroxide apexification (8,11-13). It should not be assumed, however, that every apexification case will always heal. Because trauma is the main etiology for most anterior teeth requiring treatment, undiagnosed horizontal or vertical root fractures could prevent success and might even necessitate extraction.

The presence of periapical disease in conjunction with an endodontically involved tooth indicates infection of the root canal and possibly the periapical tissue with pathogenic bacteria (16-18). Because of the flaring characteristics of the wide open apex, removal of necrotic debris and bacteria is difficult (19). The greater the size of apex opening, the more difficult canal instrumentation becomes. If necrotic debris and bacteria cannot be removed from the apical portion of the root canal, then periapical inflammation is more likely to persist. The results of this study indicate that patients who present with a combination of open apex, necrotic pulp, and sizeable periapical radiolucency (>5 mm) are at greater risk for developing painful interappointment symptoms. This relationship proved statistically significant even though the number of patients who developed painful interappointment symptoms was

Table 3. Correlation coefficients for four clinical variables

Clinical variables	Correlation Coefficients
Closure time - Apex Opening	0.22
Closure time - Radiolucency	0.15
Closure time - Age	-0.03
Apex Opening - Age	-0.07
Radiolucency - Age	0.23
Radiolucency - Apex Opening	0.51*

* p < 0.01

Note: Represents only the 26 cases with a radiolucency.

relatively small ($n=9$). The use of prophylactic antibiotics when treating such cases could possibly reduce or eliminate the risk of interappointment flare-ups. Morse and coworkers (20) compared two groups of patients receiving endodontic therapy because of pulpal-periapical lesions. The group that received prophylactic penicillin had a significantly reduced risk of developing a flare-up compared to the group that received no antibiotic therapy.

If painful interappointment symptoms occurred, closure of the root apex was delayed by approximately 5 months. Periapical inflammation caused by a bacterial infection could reverse or delay formation of an apical barrier. Treatment of these flare-ups by reinstrumenting the root canal, replacing the calcium hydroxide paste, and prescribing appropriate antibiotics facilitated healing and allowed continued formation of the apical barrier.

The authors decided which form of calcium hydroxide to use based upon the material's handling characteristics. Many different formulations of calcium hydroxide have been used for many years with no evidence that one product is more advantageous than another (21). At the present time, however, there appears to be little value in combining calcium hydroxide with antibacterial chemicals since calcium hydroxide by itself is a potent bactericide.

In this study the calcium hydroxide paste was changed every 3–6 months. The literature is varied on how often open apex teeth should be debrided and repacked with calcium hydroxide. Some authors recommend repacking every three to six months (19), repacking only in the presence of symptoms (22), repacking if the paste appears less dense radiographically (23), or only when checking for a hard tissue barrier (24). Each technique has been shown to be successful. Young patients, however, might not be aware of problems such as the loss of a temporary restoration or the development of a sinus tract. The 3 month time interval was chosen in this study because the authors wished to verify soft tissue health and test the integrity of the temporary restoration. Since an apical barrier cannot always be detected radiographically (1), the development of such a barrier was checked physically with an endodontic file at each recall interval.

Forty percent of the anterior teeth receiving treatment discolored during apexification. Although there was no statistically significant relationship between tooth discoloration and any of the variables studied, there was a tendency for teeth to discolor if treatment continued beyond one year. Microleakage of the temporary filling material or other factors may be responsible for this clinical finding. It was possible to restore an acceptable appearance to these teeth by endodontic bleaching after gutta-percha obturation.

When all the patients were grouped together (symptoms and no symptoms), there was no correlation between size of apex opening, size of radiolucency, or age when compared to closure time. This means that the initial size of apex opening, size of radiolucency, or age are not reliable predictors of how long it will take to achieve apical closure. Only Ghose (13) compared these relationships. His finding that there was no statistically significant relationship between size of apex opening and closure time was confirmed in this study.

A statistically positive correlation existed between the size of apical radiolucency and the size of apex opening. This finding seemed logical because a large root canal and apex opening would provide space for a greater volume of necrotic debris and bacteria and would present a greater periapical contact area for these irritants. The authors sometimes found it difficult to distinguish between a pathologic radiolucency and the normal radiolucency associated with the developing root apex. Comparisons with the adjacent and contralateral teeth were used in these measurement determinations (25).

It was not necessary for a periapical radiolucency to completely resolve in order for apexification to occur. In several instances apexification preceded resolution of a radiolucency. This was illustrated in Figs. 4 and 5. Large radiolucencies may take several years to completely resolve. There is recent evidence that some radiolucent lesions and associated bacterial infections may be refractory to conventional endodontic therapy (26). Because it may be possible for apexification to occur in the presence of a chronic bacterial infection, periodic recall examination is necessary to insure complete periapical healing.

Conclusions

- Trauma was the etiology of pulpal necrosis in almost every instance of an anterior tooth requiring apexification. Caries was the etiology for posterior teeth.
- Closure time for all cases took approximately 1 year \pm 7 months.
- Nine patients suffered painful interappointment symptoms. When this occurred it usually involved a tooth with a relatively large radiolucency (5.9 mm average size).
- If painful interappointment symptoms occurred, closure time was delayed an additional 5 months compared to patients without symptoms.
- Forty percent of the anterior teeth in this study developed coronal discoloration.
- Although treatment time was prolonged for some individuals (>2 years), closure of the root apex allowing completion of non-surgical endodontic

therapy was achieved for every patient in this study.

Acknowledgement – The authors thank Dr. George E. Fryer for his assistance in the statistical preparation of the data.

References

1. INGLE JI, TAINTOR JF. Endodontics. Philadelphia: Lea & Febiger, 1985: 754–60.
2. FRANK AL. Therapy for the divergent pulpless tooth by continued apical formation. *JADA* 1966; 72: 87–9.
3. STEINER JC, VAN HASSEL HJ. Experimental root apexification in primates. *Oral Surg Oral Med Oral Pathol* 1971; 31: 409–15.
4. HAM JW, PATTERSON SS, MITCHELL DF. Induced apical closure of immature pulpless teeth in monkeys. *Oral Surg Oral Med Oral Pathol* 1972; 33: 438–49.
5. TORNECK CD, SMITH JS, GRINDALL P. Biologic effect of endodontic procedures on developing incisor teeth. IV. Effect of debridement procedures and calcium hydroxide-camphorated parachlorophenol paste in the treatment of experimentally induced pulp and periapical disease. *Oral Surg Oral Med Oral Pathol* 1973; 35: 541–54.
6. HEITHERSAY GS. Stimulation of root formation in incompletely developed pulpless teeth. *Oral Surg Oral Med Oral Pathol* 1970; 29: 620–30.
7. TRONSTAD L, ANDREASEN JO, HASSELGREN G, KRISTERSON L. pH changes in dental tissues after root canal filling with calcium hydroxide. *J Endod* 1981; 7: 17–21.
8. BYSTÖM A, CLAESSON R, SUNDQVIST G. The antibacterial effect of CPC, CP and CH in the treatment of infected root canals. *Endod Dent Traumatol* 1985; 1: 170–5.
9. COOKE C, ROWBOTHAM TC. Root canal therapy in nonvital teeth with open apices. *Br Dent J* 1960; 108: 147–50.
10. STEINER JC, DOW PR, CATHEY GM. Inducing root end closure of non-vital permanent teeth. *J Dent Child* 1968; 35: 47–54.
11. THATER M, MARECHAUX SC. Induced root apexification following traumatic injuries of the pulp in children: follow-up study. *J Dent Child* 1988; May-June: 190–5.
12. CVEK M, HOLLENDER L, NORD CE. Treatment of non-vital permanent incisors with calcium hydroxide. VI. A clinical, microbiological and radiological evaluation of treatment in one sitting of teeth with mature or immature root. *Odontol Revy* 1976; 27: 93–108.
13. GHOSE LJ, BAGHDADY VS, HIKMAT BYM. Apexification of immature apices of pulpless permanent anterior teeth with calcium hydroxide. *J Endod* 1987; 13: 285–90.
14. KLEIER DJ, AVERBACH RE, KAWULOK TC. Efficient calcium hydroxide placement within the root canal. *Oral Surg Oral Med Oral Pathol* 1985; 53: 509–10.
15. ANDREASEN JO. Traumatic injuries of the teeth. Philadelphia: Saunders, 1981: 41.
16. YOSHIDA M, FUKUSHIMA H, YAMAMOTO K, et al. Correlation between clinical symptoms and microorganisms isolated from root canals of teeth with periapical pathosis. *J Endod* 1987; 13: 24–8.
17. SUNDQVIST G. Bacteriological studies of necrotic dental pulps. Umea University Odontological Dissertations No. 7, Umeå, Sweden, 1976.
18. MOLLER A, FABRICIUS L, DAHLEN G, OHMAN A, HEYDEN G. Influence on periapical tissues of indigenous oral bacteria and necrotic pulp tissue in monkeys. *Scand J Dent Res* 1981; 89: 475–84.
19. DUELL RC. Conservative endodontic treatment of the open apex in three dimensions. *Dent Clin North Am* 1973; 17: 125–34.
20. MORSE DR, FURST LM, LEFKOWITZ RD, SIDEMAN BH. Prophylactic penicillin versus penicillin taken at the first sign of swelling in cases of asymptomatic pulpalperiapical lesions: a comparative analysis. *Oral Surg Oral Med Oral Pathol* 1988; 65: 228–32.
21. INGLE JI, TAINTOR JF. Endodontics. Philadelphia: Lea & Febiger, 1985: 756–7.
22. COHEN S, BURNS RC. Pathways of the pulp. St. Louis: Mosby, 1987: 713–8.
23. GERSTEIN H. Techniques in clinical endodontics, Philadelphia: Saunders, 1983: 162–71.
24. CHAWLA HS. Apical closure in a nonvital permanent tooth using one CA(OH)₂ dressing. *ASDC J Dent Child* 1986; Jan-Feb: 44–7.
25. WALTON RE, TORABINEJAD M. Principles and practice of endodontics. Philadelphia: Saunders, 1989: 374.
26. TRONSTAD L, BARNETT F, CERVONE F. Periapical bacterial plaque in teeth refractory to endodontic treatment. *Endod Dent Traumatol* 1990; 6: 73–77.

This document is a scanned copy of a printed document. No warranty is given about the accuracy of the copy. Users should refer to the original published version of the material.