

## A CLINICAL, ROENTGENOGRAPHIC, AND HISTOPATHOLOGIC EVALUATION OF PERIAPICAL LESIONS

*William B. Linenberg, D.D.S., M.S.D.,\* Westfield, N. J., Charles A. Waldron, D.D.S., M.S.D.,\*\* Atlanta, Ga., and Gerald F. DeLaune, Jr., D.D.S.\*\*\* Ferriday, La.*

DIAGNOSIS of periapical areas of rarefaction has always been a problem to the oral surgeon and general practitioner. A review of the literature reveals few studies<sup>1-3</sup> of apical roentgenolucent areas in the last 10 years. These investigations have concerned themselves mainly with teeth that have had extensive restorative and endodontic treatment. A study was undertaken to (1) evaluate, roentgenographically and clinically, areas of periapical rarefaction in persons who have never sought definitive dental treatment and (2) evaluate histopathologically the specimens obtained from these areas.

Periapical roentgenolucent areas are usually diagnosed as cysts, granulomas, or chronic periapical abscesses. However, a differential diagnosis including, among others, Paget's disease, eosinophilic granuloma, fibrous dysplasia, Hand-Schüller-Christian disease, and neoplasms should be kept in mind.

Criteria for the roentgenologic diagnosis of periapical pathoses have received considerable attention in the literature. McCall and Wald<sup>4</sup> have defined a cyst as a circumscribed radiolucent area, usually more than  $\frac{3}{8}$  inch in diameter, sharply outlined, and bound by a thin, even, white line which represents a layer of cortical bone. A granuloma has been defined as a definite radiolucency without the presence of a white line and usually less than  $\frac{3}{8}$  inch in diameter. A chronic periapical abscess appears as a diffuse radiolucent area, usually accompanied by resorption of the root end of the involved teeth.

Stafne<sup>5</sup> also stated that the roentgen image of a dental granuloma is generally not as definite or as well demarcated as the small, fully developed cyst. He further states that granulomas and radicular cysts of equal size cannot be distinguished roentgenographically from each other. Granulomas, however, seldom exceed 1 cm. in diameter.

The accuracy and validity of roentgenologic diagnosis of periapical lesions

---

\*Formerly Post Oral Surgeon, Fort Gordon, Ga. Present address: 414 Lenox Ave., Westfield, N. J.; Diplomate, American Board of Oral Surgery.

\*\*Professor of Pathology, Emory University, School of Dentistry, Atlanta, Ga.

\*\*\*Formerly Oral Surgeon, United States Army Garrison, Fort Gordon, Ga.

in this category have been challenged by several authors. The studies of Priebe and associates,<sup>1</sup> Baumann and Rossman,<sup>2</sup> and Wais<sup>3</sup> have all demonstrated the lack of correlation between roentgenologic and histologic diagnoses of periapical pathologic conditions. Priebe and his associates noted that the oral surgeon and the radiologist correctly diagnosed only 13 per cent of fifty-five periapical cysts by means of the roentgenogram alone. Baumann and Rossman found that a correct diagnosis of cyst was made in 50 per cent of 121 cases when clinical and roentgenologic criteria were used. Wais submitted fifty specimens, all of which were considered to be cysts, according to roentgenologic and clinical criteria, but microscopic study revealed that only 26 per cent of these lesions actually were cysts.

Recent experimental studies by Bender and Seltzer<sup>6</sup> and by Ramadan and Mitchell<sup>7</sup> have further emphasized the limitations of roentgenographic interpretation of periapical bone destruction. Their work casts further doubt on the validity of the use of rigid roentgenographic differential diagnostic criteria for lesions in this category.

#### MATERIALS AND METHODS

One hundred ten periapical biopsy specimens were taken from sixty-eight basic recruits at Fort Gordon, Georgia. The patients were healthy young male soldiers between 17 and 25 years of age; their average age was 19.6 years.

A random sampling technique was used in the selection of patients. Most of the patients studied in the clinical investigation had never been to a dentist. Those patients who had been to a dentist previously had received only emergency care and no definitive restorative treatment. In none of the patients had roentgenograms of the mouth been taken prior to this study. Complete-mouth roentgenograms were taken for the investigation, and multiple biopsies were performed in twenty-seven cases.

All specimens were taken from the apices of nonrestorable teeth. In the majority of patients, the biopsy specimens were obtained from residual roots.

All areas of rarefaction, regardless of size, were biopsied. The appearance of the tooth (caries), the tissue surrounding the tooth prior to extraction (color, inflammation, fistulous tract), and the presence of pain and/or cellulitis were recorded in each case. The surgical enucleation of the specimen was also noted.

Of the 110 biopsies, sixty-three (57.2 per cent) involved maxillary and mandibular first molars. From the eruption standpoint, these teeth had been in the mouth longer than any other tooth.

All the specimens were fixed immediately in 10 per cent formalin and sent to the Pathology Department of Emory University School of Dentistry. In each case the oral surgeon made a diagnosis from the roentgenogram and the clinical specimen.

The tissue specimens were processed in the usual manner and stained with hematoxylin and eosin. The gross specimens were blocked, so that multiple areas of each specimen could be visualized. The histologic criteria used for interpretation of the specimens were those generally employed by oral pathologists. Defi-

nite evidence of a central cavity with an epithelium-lined lumen was considered necessary for the diagnosis of a cyst. The diagnosis of granuloma was made when the specimen showed a circumscribed mass of chronic inflammatory tissue without notable central necrosis or lumen formation. If proliferating epithelium or epithelial rests were present, the lesion was still considered to be a granuloma unless definite lumen formation could be noted. A diagnosis of chronic periapical abscess was made when central necrosis and a fairly dense accumulation of polymorphonuclear leukocytes were seen surrounded by an inflamed connective tissue wall of variable thickness.

#### CLINICAL FINDINGS

If the roentgenogram showed a well-defined, circumscribed roentgenolucent area and if the pathosis was removed with the tooth or easily curetted out of the socket, the lesion was clinically diagnosed as a cyst, regardless of size. When the roentgenogram showed a definite roentgenolucent area and the pathosis was not removed as readily as a cyst, the lesion was clinically designated as a granuloma. Size did not enter into the diagnosis. If a diffuse roentgenolucent area appeared on the roentgenogram and considerable curettage was required to remove the tissue, the lesion was diagnosed as a periapical abscess. In most of these cases, the tissue was removed from the socket in a "shredded" condition.

On the basis of these criteria, the clinicians diagnosed forty-six lesions as cysts, fifty as granulomas, thirteen as periapical abscesses, and one as periodontitis.

Twenty-four of the sixty-eight patients complained at some time of pain associated with the tooth or lesion being biopsied. However, forty-four of the patients denied ever having had pain associated with the involved tooth. Fistulas were present in six cases at the time of treatment.

#### MICROSCOPIC FINDINGS

During the course of the study, the difficulty in rigid histologic classification and separation of the lesions in this group became increasingly apparent. Review of multiple sections emphasized the close relationship between periapical cysts, granulomas, and chronic abscesses. Many cases showed features of all three, and others suggested transitions from one to another.

The final microscopic interpretation of the 110 specimens was recorded as follows:

- Mature radicular cyst—10
- Early radicular cyst—21
- Granuloma—68
- Chronic periapical abscess—6
- Periodontitis—5

Placement of some of the cases in several of these categories may be open to argument and, admittedly, the classification was somewhat arbitrary in some instances. The twenty-one lesions classified as early radicular cysts were placed into this group because of epithelial proliferation with what appeared to be

early lumen formation. Undoubtedly, some pathologists would prefer to consider some of these lesions as granulomas with epithelial proliferation. This is an entirely personal matter and serves to emphasize the many transitions between granuloma and cyst. Not all members of the Pathology Department who reviewed these cases were in agreement as to classification of some of the lesions. The six lesions classified as chronic periapical abscess might also be considered by some to be granulomas. The difficulty in separating these lesions has also been noted by others.<sup>2</sup>

A diagnosis of periodontitis was made in five cases. Each of these specimens presented a strip of inflamed connective tissue surfaced by proliferating epithelium which appeared to be of obvious gingival origin. Review of the roentgenograms in these cases invariably showed residual roots or badly broken-down teeth with rarefied areas extending to the alveolar crest. In some cases it was impossible to determine whether the primary lesion was periapical or gingival, but the diagnosis of periodontitis appeared most appropriate.

#### CLINICOPATHOLOGIC CORRELATION

A comparison of the clinical and pathologic findings is shown in Table I.

Using the roentgenogram and the operative findings as the basis for diagnosis, the surgeons were in agreement with the pathologists' findings in 66 of the 110 cases (60 per cent) (Figs. 1 to 4).

#### DISCUSSION

The results of this study are in general agreement with previous clinicopathologic evaluations of periapical pathosis<sup>1-3</sup> and further serve to demonstrate the difficulty in making accurate diagnoses on the basis of clinical and roent-

TABLE I

PATHOSIS	CLINICIANS' DIAGNOSIS	PATHOLOGISTS' DIAGNOSIS	CORRECT DIAGNOSIS BY CLINICIAN
Cyst	46	Mature 10 Early 21	7 16
Granuloma	50	68	38
Chronic periapical abscess	13	6	4
Periodontitis	1	5	1

genologic criteria. This is particularly true when the area of periapical roentgenolucency is less than 0.15 cm. in diameter. The highest correlation was in the group of lesions diagnosed as cysts, either mature or early, where the clinicians were in agreement with the pathologists' diagnosis in 74 per cent of the cases. However, the clinicians' diagnosis of granuloma was in agreement with the pathologists' diagnosis in only 56 per cent of the cases.

For the first time, to the best of our knowledge, a clinical study was undertaken to evaluate patients who had not had any previous definitive dental treatment. Some of these patients had previously consulted dentists for emergency extractions, but none of them had undergone any roentgenographic examination

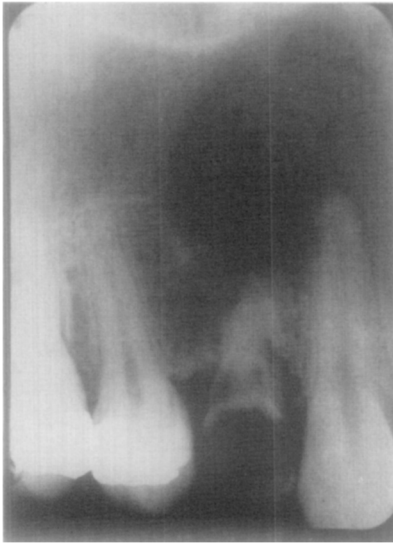

Fig. 1.

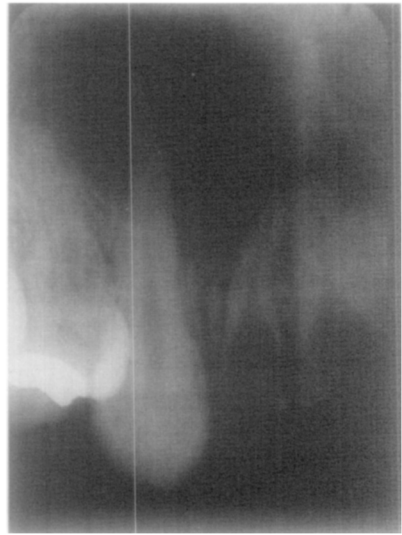


Fig. 2.

Fig. 1.—Large radicular cyst of maxilla. Roentgenographically and clinically, this lesion was considered to be a cyst. Microscopic examination showed a typical cyst.

Fig. 2.—A similar lesion which, on the basis of roentgenographic and clinical criteria, was considered to be a cyst. Multiple microscopic sections showed a typical dental granuloma.

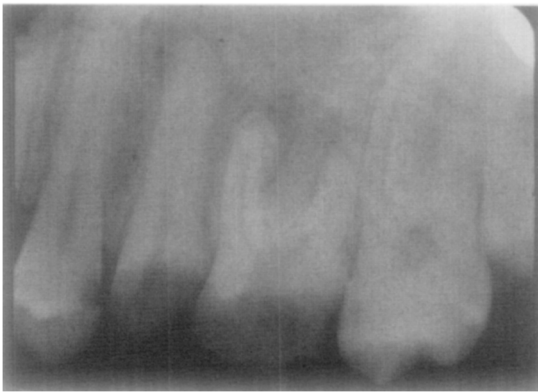

Fig. 3.

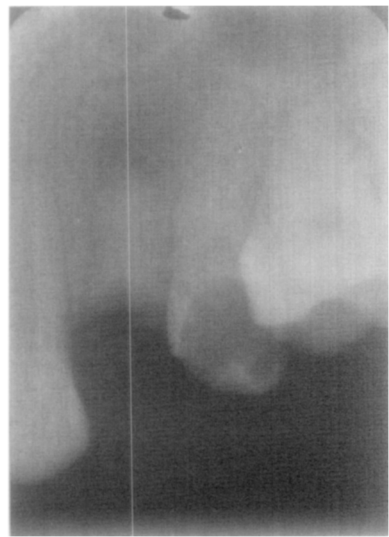


Fig. 4.

Figs. 3 and 4.—Small roentgenolucent areas which would be considered typical granulomas by roentgenographic and clinical criteria. In both instances the lesions were small but mature radicular cysts.

prior to this study. It is interesting to note that complete-mouth roentgenograms in these patients revealed no areas of residual pathosis in any edentulous area. In view of the very poor oral condition of most of the subjects and the number of lesions involving first permanent molars, it could be presumed that the pathosis was of relatively long duration in many cases. It is therefore surprising

that such a low incidence of mature radicular cysts was found. In addition, most of the lesions encountered were less than 0.5 cm. in diameter, in spite of the presumed long duration of disease in the involved teeth.

#### SUMMARY

1. A clinical-pathologic study was conducted on 110 periapical specimens obtained from sixty-eight male basic recruits with an average age of 19.6 years.

2. None of these patients had ever received definitive dental care or had previous roentgenologic examination.

3. Microscopic diagnosis of the periapical lesions was cyst in thirty-one cases, granuloma in sixty-eight cases, chronic periapical abscess in six instances, and periodontitis in five cases.

4. Sixty-three of the specimens (57.2 per cent) were obtained from maxillary and mandibular first molars.

5. The clinical diagnosis, based on roentgenographic and operative findings, was in agreement with the pathologist's diagnosis in sixty-six (60 per cent) of the cases.

#### CONCLUSIONS

Although the roentgenogram is extremely important in determining the presence of an area of rarefaction, the structures involved, and the extent of the destructive process, an accurate diagnosis of periapical pathosis can be determined with certainty only by microscopic evaluation.

The authors wish to acknowledge the clinical assistance of Dr. Richard T. Hart in obtaining the biopsy specimens.

#### REFERENCES

1. Priebe, W. A., Lazansky, J. P., and Wuehrmann, A. H.: The Value of the Roentgenographic Film in the Differential Diagnosis of Periapical Lesions, *ORAL SURG., ORAL MED. & ORAL PATH.* 7: 979-983, 1954.
2. Baumann, L., and Rossman, S. R.: Clinical, Roentgenologic, and Histopathologic Findings in Teeth With Apical Radiolucent Areas, *ORAL SURG., ORAL MED. & ORAL PATH.* 9: 1330-1336, 1956.
3. Wais, F. T.: Significance of Findings Following Biopsy and Histologic Study of 100 Periapical Lesions, *ORAL SURG., ORAL MED. & ORAL PATH.* 11: 650-653, 1958.
4. McCall, J. O., and Wald, S. S.: Clinical Dental Roentgenology, ed. 3, Philadelphia, 1952, W. B. Saunders Company, pp. 192-193.
5. Stafne, E. C.: Oral Roentgenographic Diagnosis, ed. 2, Philadelphia, 1963, W. B. Saunders Company, p. 73.
6. Bender, I. B., and Seltzer, S.: Roentgenographic and Direct Observation of Experimental Lesions in Bone, *J. Am. Dent. A.* 62: 708-716, 1961.
7. Ramadan, A. E., and Mitchell, D. F.: Roentgenographic Study of Experimental Bone Destruction, *ORAL SURG., ORAL MED. & ORAL PATH.* 15: 934-943, 1962.