

---

# Frequency and type of canal isthmuses in first molars detected by endoscopic inspection during periradicular surgery

**T. von Arx**

Department of Oral Surgery and Stomatology, School of Dental Medicine, University of Berne, Berne, Switzerland

---

## Abstract

**von Arx T.** Frequency and type of canal isthmuses in first molars detected by endoscopic inspection during periradicular surgery. *International Endodontic Journal*, **38**, 160–168, 2005.

**Aim** To analyse the occurrence of canal isthmuses in molars following root-end resection.

**Methodology** The material consisted of 56 mandibular and 32 maxillary first molars subjected to periradicular surgery. Based on radiographic, clinical, as well as intraoperative status, only roots with associated pathological lesions were treated. In total, 124 roots were resected (80 mandibular and 44 maxillary molar roots). The cut root faces were inspected with a rigid endoscope following apical root-end resection. The number of canals as well as the presence and type of canal isthmuses were recorded.

**Results** In maxillary first molars, 76% of resected mesio-buccal roots had two canals and an isthmus,

10% had two canals but no isthmus, and 14% had a single canal. All disto-buccal and palatal roots had one canal. In mandibular first molars, 83% of mesial roots had two canals with an isthmus. In 11%, two canals but no isthmus were present, and 6% demonstrated a single canal. Sixty-four per cent of distal roots had a single canal and 36% had two canals with an isthmus.

**Conclusions** This clinical study during periradicular surgery and intraoperative endoscopic examination of first permanent molars found a high frequency of canal isthmuses at the resection level. Endoscopic inspection also demonstrated that none of the isthmuses were filled, emphasizing the difficulty of orthograde instrumentation and root filling of canal isthmuses.

**Keywords:** canal isthmus, endoscopy, molar, periradicular surgery, root-end resection.

*Received 19 July 2004; accepted 21 October 2004*

---

## Introduction

A canal isthmus is generally defined as a narrow, ribbon-shaped communication between two root canals that contains pulp tissue (Weller *et al.* 1995). The incidence of canal isthmuses varies for type of tooth and level within a given root (Vertucci 1984), but also appears to be age-related (Al Shalabi *et al.*

2000). The incidence of canal isthmuses in first molars ranges from 54 to 89% in mesial roots of mandibular first molars, and from 5 to 53% in mesio-buccal roots of maxillary first molars (Hsu & Kim 1997). The incidence of isthmuses has been reported to be highest 4–6 mm from the apex in mesial roots of mandibular first molars, and 3–5 mm from the apex in mesio-buccal roots of maxillary first molars (Weller *et al.* 1995, Hsu & Kim 1997).

The canal isthmus has its clinical significance in two fields of dentistry: conventional root canal treatment and periradicular surgery. As mechanical cleaning and shaping of a canal isthmus is difficult and ineffective, it must be considered in failures following conventional

---

Correspondence: Dr Thomas von Arx, PD, Department of Oral Surgery and Stomatology, School of Dental Medicine, University of Berne, Freiburgstrasse 7, CH-3010 Berne, Switzerland (Tel.: +41-31-632-2566; fax: +41-31-632-9884; e-mail: thomas.vonarx@zmk.unibe.ch).

orthograde root canal treatment. In periradicular surgery, a canal isthmus, when overlooked, can also lead to failure (Hsu & Kim 1997).

With the advent of microsurgical principles using microinstruments and magnification devices, the canal isthmus can be identified and prepared during periradicular surgery (Kim 1997, von Arx & Walker 2000). The recognition and management of the canal isthmus is an important factor that could improve the success rate of periradicular surgery in posterior teeth (Rubinstein & Kim 1999, 2002).

In a recent *in-vitro* study analysing the diagnostic accuracy of endoscopy compared with scanning electron microscopy for detection of microstructures following apical root-end resection, a 100% specificity and sensitivity was found for endoscopic identification of the canal isthmus (von Arx *et al.* 2003). It was concluded that the endoscope could be recommended

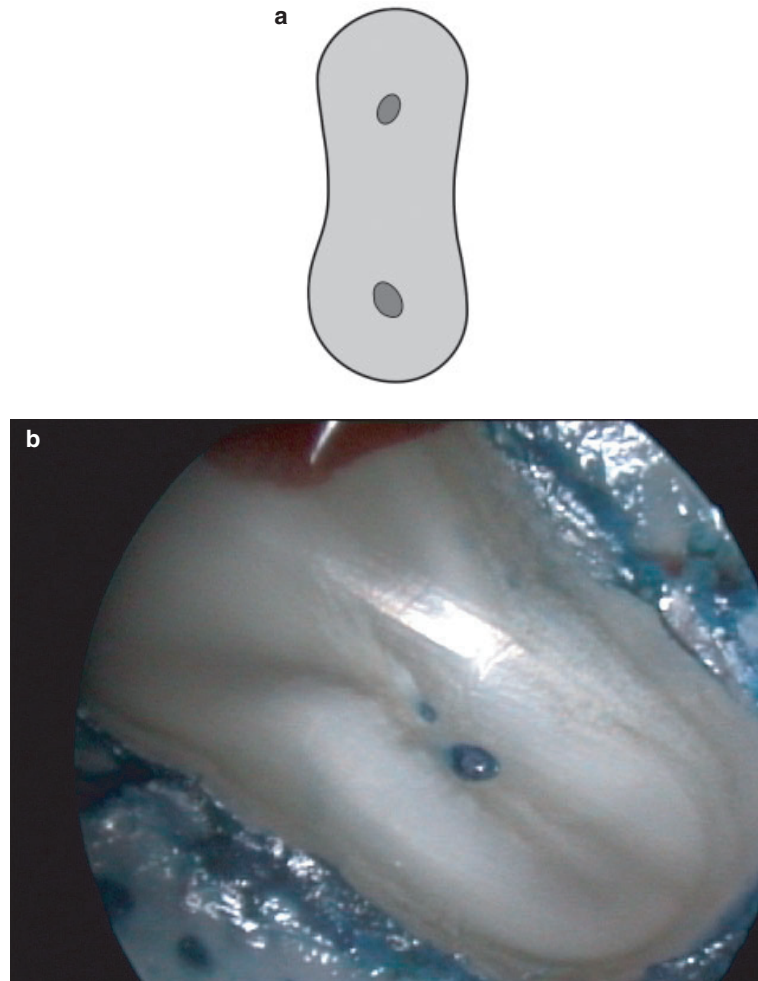
for diagnosis of the cut root face in periradicular surgery.

The objective of the present clinical study was twofold: to assess the presence of a canal isthmus in molars during periradicular surgery using an endoscope, and to determine the type of canal isthmus present at the cut root face.

## Materials and methods

### Patient selection

Patients referred for periradicular surgery in molars were consecutively enrolled. Patients were fully instructed about the surgical procedure, postoperative care and prognosis, and alternative treatment options. Informed and written consent was obtained. Main exclusion criteria were general medical contraindications.



**Figure 1** Mesial root of a mandibular first molar showing two canals without a communication (type I) at the cut root face.

tions for (oral) surgical procedures and a concomitant, advanced marginal periodontitis.

Overall, 35 maxillary and 60 mandibular permanent molars were treated. As second molars were seldom treated, they were subsequently excluded for isthmus evaluation. A total of 32 first maxillary molars and 56 first mandibular molars were included in the present study.

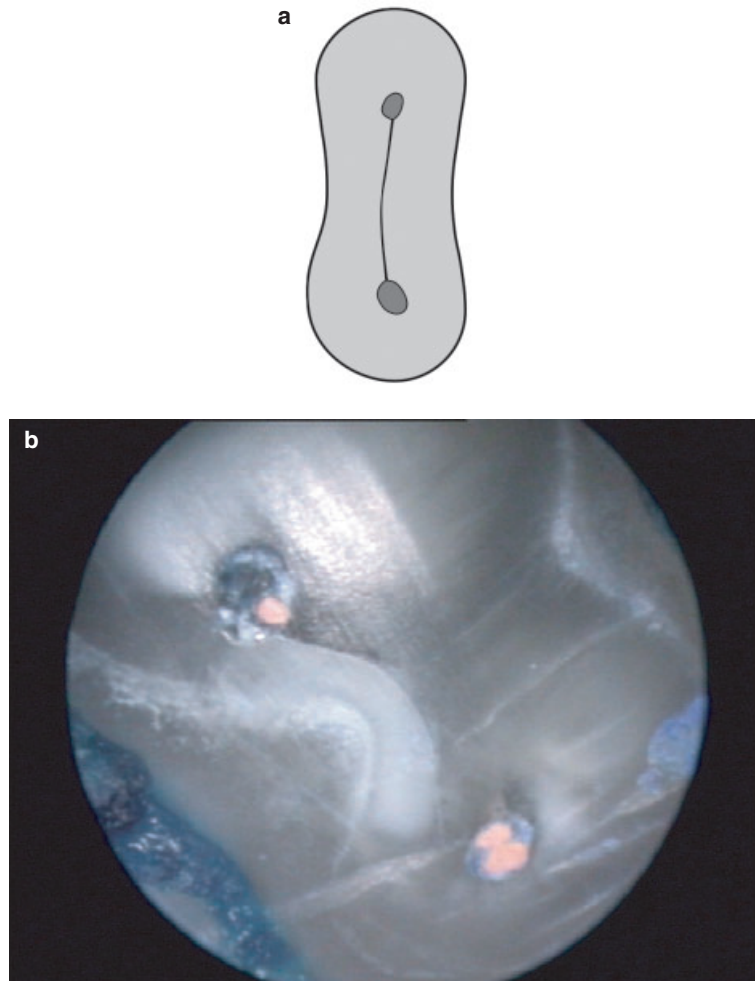
### Surgical technique

Periradicular surgery was performed under local anesthesia in an operating room. Following an intra-sulcular incision extending to both adjacent teeth and a mesial release incision, a triangular full mucoperiosteal flap was raised. When necessary, a distal release incision was made for trapezoidal flap elevation. Osteotomies were performed with round burs under copious saline irrigation. Affected roots were resected

approximately 3–4 mm by grinding down the root-end with a small round bur with subsequent flattening of the cut root-face using a fissure bur. Following debridement of all pathological tissue, haemostasis of the bony crypt was achieved with an aluminium-chloride containing paste (Expasyl; Produits Dentaires Pierre Rolland, Merignac, France). Following endoscopic inspection (see below), root-end cavities were prepared and filled with either SuperEBA (Stident International, Staines, UK), MTA (Dentsply Tulsa Dental, Tulsa, OK, USA) or Retroplast (Retroplast Trading, Ronne, Denmark). Primary wound closure was accomplished with multiple interrupted sutures.

### Isthmus evaluation

Methylene blue was utilized for vital tissue staining (Cambruzzi *et al.* 1985). This method allowed the distinction of organic from inorganic tissues, and was



**Figure 2** Mesio-buccal root of a maxillary first molar with a type II canal isthmus represented by a fine line connecting the two canals at the resection level.

helpful locating the periodontal ligament, accessory canals, unfilled canals, canal isthmuses, cracks and root fractures. The number of canals at the cut root face and the presence and type of canal isthmuses were recorded. Isthmuses were classified according to Hsu & Kim (1997). Type I is defined as two canals with no notable communication (Fig. 1). Type II is defined as a hair-thin connection between the two main canals (Fig. 2). Type III differs from the latter only with the presence of three canals instead of two (Fig. 3). Type IV has an isthmus with extended canals into the connection (Fig. 4). Type V is recognized as a true connection or wide corridor of tissue between the two main canals (Fig. 5).


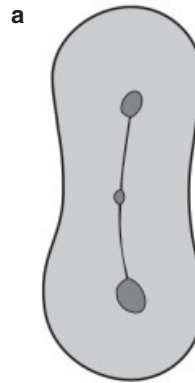
For magnification and visualization, a 3-mm wide rigid endoscope (Hopkins Tele-Otoscope 70°; Karl Storz GmbH, Tuttlingen, Germany) (von Arx *et al.* 2002) was placed close to the root end (Fig. 6). Magnification

ranged from  $\times 50$  to  $\times 100$  depending on the distance between the lens and the root end. A digital camera coupled to the ocular of the endoscope transmitted the image to a video screen placed opposite the surgeon, and to a video recorder.

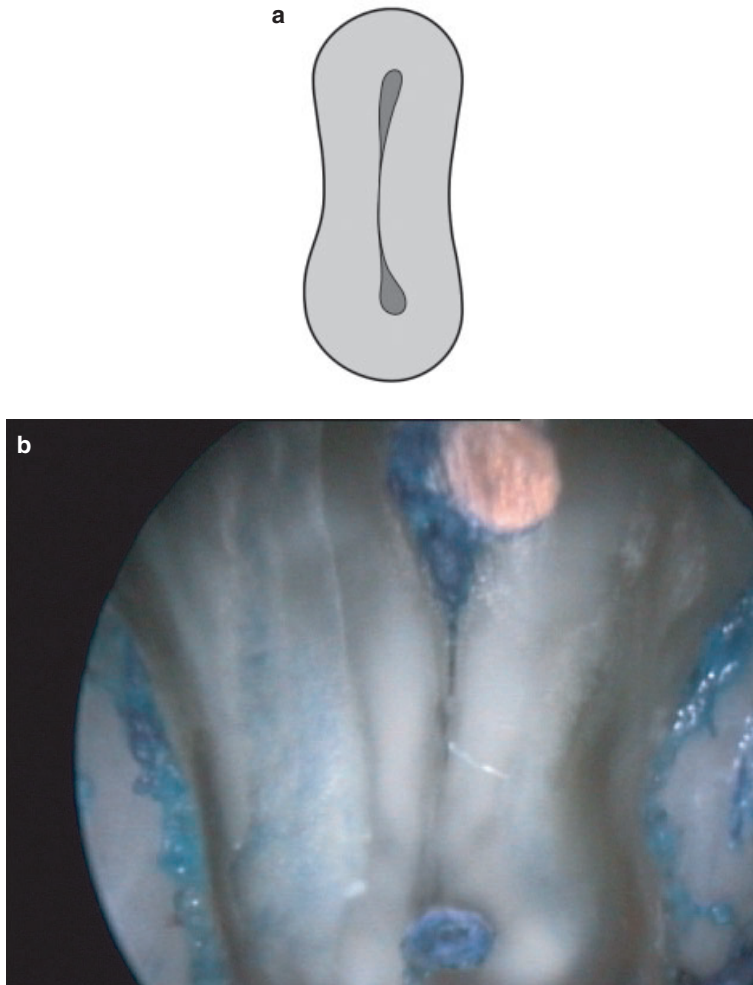
## Results

A total of 124 roots were analysed in 88 first permanent molars (Table 1). The root most often treated was the mesial root of mandibular first molars (42%).

A canal isthmus was present in 76% of mesio-buccal roots in maxillary first molars, in 83% of mesial roots in mandibular first molars, and in 36% of distal roots in mandibular first molars. None of the canal isthmuses had been filled by the previous orthograde root canal treatment. An isthmus was



**Figure 3** Mesio-buccal root of a maxillary first molar with a type III canal isthmus characterized by an additional canal in the middle of the isthmus.



**Figure 4** Mesial root of a mandibular first molar with two canals extending into the isthmus (type IV canal isthmus).

never found in disto-buccal and palatal roots of maxillary first molars (Table 2).

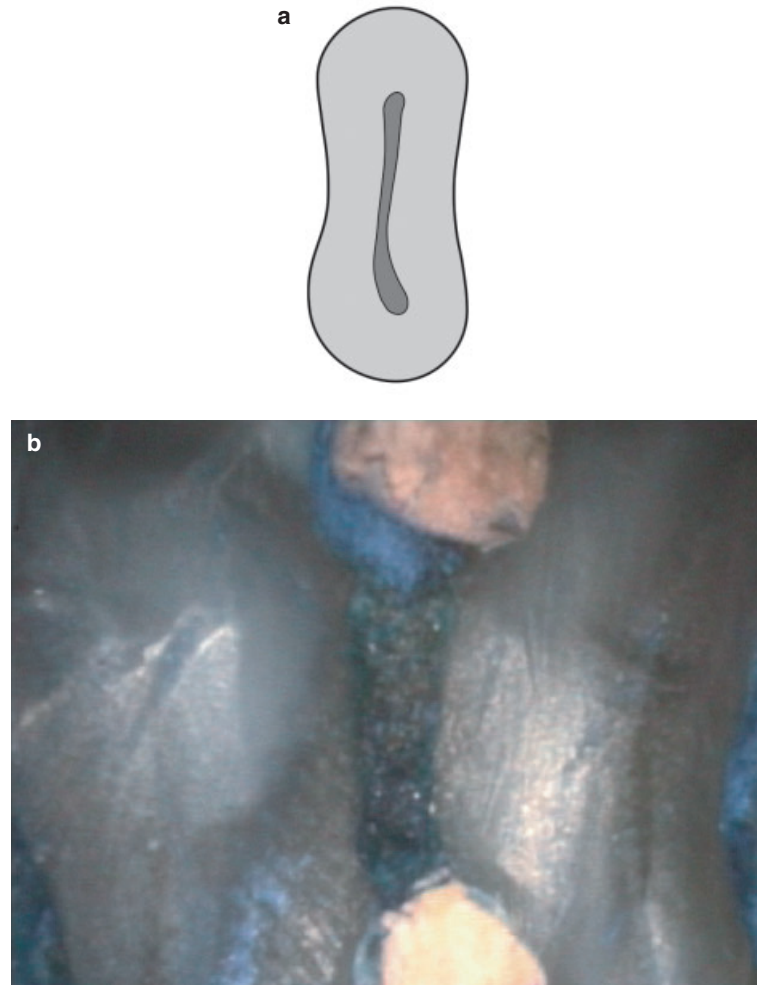
Mesio-buccal roots in maxillary first molars most often showed a type II isthmus (hair-like thin tissue connection). In mesial roots of mandibular first molars, type IV (canals extending into isthmus) and type V (broad tissue connection between canals) configurations were found more frequently than type II (Table 3). In distal roots of mandibular first molars, a type V isthmus was most likely when an isthmus was present.

## Discussion

This study evaluated the presence and type of canal isthmuses in maxillary and mandibular first molars during periradicular surgery. The *in-vivo* approach allowed the determination of the canal configuration

only at the resection level of the cut root end during the surgical procedure. This is in contrast to *in-vitro* studies in which most often serial sections were used to evaluate the incidence and location of canals and isthmuses at different root levels.

For mesio-buccal roots of maxillary first permanent molars the incidence of canal isthmuses ranges from 5 to 53% (Hsu & Kim 1997). In studies evaluating serial sections at different levels from the apex, the highest incidence of canal isthmuses was found at 4–5 mm with incidences ranging from 19 to 100% (Weller *et al.* 1995, Hsu & Kim 1997, Tam & Yu 2002, Teixeira *et al.* 2003). The present study found a canal isthmus in 76% of mesio-buccal roots. The difficulties in cleaning and shaping the canal system of the mesio-buccal root during conventional root canal treatment may lead to eventual failure necessitating retreatment. In contrast, disto-buccal and



**Figure 5** Mesial root of a mandibular first molar with a large corridor between the two canals (type V canal isthmus).

palatal roots containing only one canal had to be surgically retreated less frequently than mesio-buccal roots.

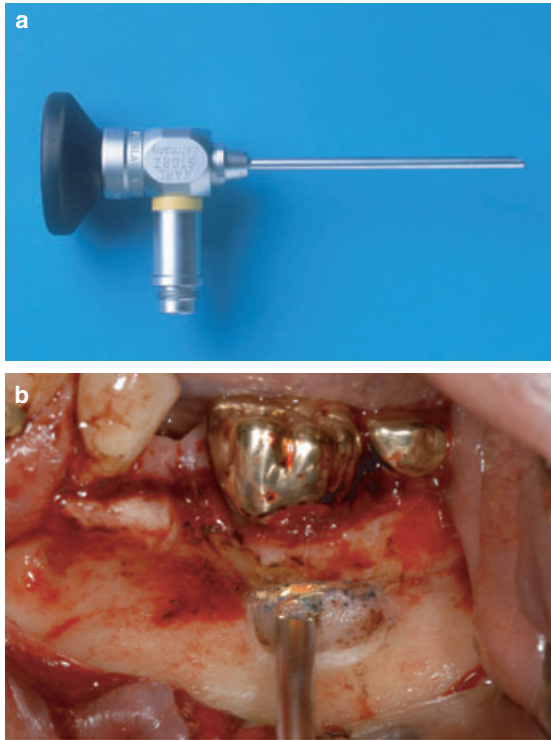
Incidences of canal isthmuses in mandibular first molars range from 54 to 89% in the mesial root, and from 15 to 17% in the distal root (Hsu & Kim 1997). Again, studies evaluating different sections show the highest incidences 4–6 mm from the apex (Hsu & Kim 1997, Teixeira *et al.* 2003). In the present study, the frequency of canal isthmuses in mandibular first molars was 83% for the mesial root and 36% for the distal root. Once again, the data of the present study corroborate the findings of the *in-vitro* studies.

The presence of a canal isthmus has been reported as one of the major reasons for failure following surgical and non-surgical root-canal treatment in first permanent molars (Hsu & Kim 1997, Tam & Yu 2002). Any opening on the resected root surface may act as a portal

of exit. The root canal system may contain necrotic debris, tissue remnants or organic substrates that support the growth of microorganisms. A critical step in periradicular surgery is, therefore, the identification and sealing of all possible leaking microstructures.

With the advent of illumination and magnification, visualization and inspection of root apices and of resected root surfaces have become easier and more predictable (Kim 1997). The use of surgical microscopes has been widely accepted in conventional and surgical endodontics (Mines *et al.* 1999). One clinical study evaluated the identification of the second canal (mb2) in the mesio-buccal root of maxillary molars over an 8-year period (Stropko 1999). Without magnification, the mb2 canal was located in 73.2% of first molars. When employing the microscope routinely, this number increased to 93%. This enhanced location of the canal orifice and/or negotiation of the mb2 canal in





**Figure 6** (a) Rigid endoscope with rod lens system (Tele Oscope, 6 cm long, 3 mm wide, 70° viewing angle). (b) The tip of the endoscope has been placed into the bony crypt opposite the cut root face.

mesio-buccal roots of maxillary (first) molars using an operating microscope has been corroborated by several *in-vitro* studies (Görduysus *et al.* 2001, Baldassari *et al.*

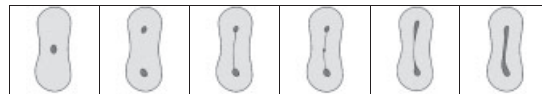
**Table 1** Number and percentage of treated roots ( $n = 124$ )

	$n$ (%)
Mesial root of mandibular first molar	52 (41.9)
Mesio-buccal root of maxillary first molar	29 (23.4)
Distal root of mandibular first molar	28 (22.6)
Disto-buccal root of maxillary first molar	11 (8.9)
Palatal root of maxillary first molar	4 (3.2)
<b>Total</b>	<b>124 (100)</b>

**Table 2** Frequency of canal isthmuses ( $n = 124$ )

	One canal (no isthmus)	Two canals (no isthmus)	Two canals with isthmus
<b>Maxillary first molar</b>			
Mesio-buccal root ( $n = 29$ )	4 (14%)	3 (10%)	22 (76%)
Disto-buccal root ( $n = 11$ )	11 (100%)	–	–
Palatal root ( $n = 4$ )	4 (100%)	–	–
<b>Mandibular first molar</b>			
Mesial root ( $n = 52$ )	3 (6%)	6 (11%)	43 (83%)
Distal root ( $n = 28$ )	18 (64%)	–	10 (36%)

2002, Schwarze *et al.* 2002). In contrast, a clinical study with more stringent inclusion criteria (mb2 canal had to be negotiated and obturated to within 4 mm of the apex) could not enhance the location of mb2 canals with the use of an operating microscope (Sempira & Hartwell 2000).



**Table 3** Overview of isthmus types found in molar roots ( $n = 124$ )

Isthmus	No	No	Yes	Yes	Yes	Yes
Classification of Hsu & Kim (1997)	–	Type I	Type II	Type III	Type IV	Type V
<b>Maxillary first molar</b>						
Mesio-buccal root ( $n = 29$ )	4	3	11	1	5	5
Disto-buccal root ( $n = 11$ )	11	–	–	–	–	–
Palatal root ( $n = 4$ )	4	–	–	–	–	–
<b>Mandibular first molar</b>						
Mesial root ( $n = 52$ )	3	6	13	–	15	15
Distal root ( $n = 28$ )	18	–	2	–	2	6

The endoscope used in this study is a device that can optimize visualization in periradicular surgery. It is particularly helpful in molars with a difficult viewing angle and limited access. The endoscope can be placed into the bony crypt and in close contact to the root end. Adjustment of the viewing angle is rapid and easy. The use of a fibreoptic endoscope has been reported recently (Bahcall & Barss 2001). However, a rod lens endoscope is still recommended in surgical endodontics as it provides better image quality compared with a fibreoptic system (von Arx *et al.* 2002, Bahcall & Barss 2003).

Recently, an *in-vitro* study has demonstrated that an endoscope was significantly superior for identification of resected root end dentinal cracks compared with unaided/corrected vision, loupes or the microscope (Slaton *et al.* 2003). The diagnostic accuracy of endoscopy was corroborated in a study evaluating the specificity and sensitivity of identification of microstructures during root-end treatment of extracted molars using a rigid rod lens endoscope in comparison with scanning electron microscopy (von Arx *et al.* 2003). The sensitivity of identification of filling voids, crack formation or chipping ranged between 73 and 95%, whereas the specificity of the same parameters ranged between 77 and 100% for the endoscope compared with SEM. The specificity and sensitivity of canal isthmus detection was 100% each for the endoscope compared with SEM.

## Conclusions

- The relatively high incidence of canal isthmuses in mesio-buccal roots of maxillary first molars, and in mesial roots of mandibular molars described in *in-vitro* studies was confirmed.
- None of the canal isthmuses had been obturated by orthograde canal filling.
- In mesio-buccal roots of maxillary first molars, a type II canal isthmus prevailed, whereas mesial roots of mandibular first molars most often presented with type IV or type V canal isthmuses.

## References

- Al Shalabi RM, Omer OE, Glennon J, Jennings M, Claffey NM (2000) Root canal anatomy of maxillary first and second permanent molars. *International Endodontic Journal* **33**, 405–14.
- von Arx T, Walker W (2000) Microsurgical instruments for root-end cavity preparation following apicoectomy. *Endodontics and Dental Traumatology* **16**, 47–62.
- von Arx T, Hunenbart S, Buser D (2002) Endoscope- and video-assisted endodontic surgery. *Quintessence International* **33**, 255–9.
- von Arx T, Montagne D, Zwinggi C, Lussi A (2003) Diagnostic accuracy of endoscopy in periradicular surgery – a comparison with scanning electron microscopy. *International Endodontic Journal* **36**, 691–9.
- Bahcall J, Barss J (2001) Fiberoptic endoscope usage for intracanal visualization. *Journal of Endodontics* **27**, 128–9.
- Bahcall J, Barss J (2003) Orascope visualization technique for conventional and surgical endodontics. *International Endodontic Journal* **36**, 441–7.
- Baldassari LA, Lilly JP, Rivera EM (2002) The influence of dental operating microscope in locating the mesiolingual canal orifice. *Oral Surgery Oral Medicine Oral Pathology Oral Radiology and Endodontics* **93**, 190–4.
- Cambruzzi JV, Marshall FJ, Pappin JB (1985) Methylene blue dye. An aid to endodontic surgery. *Endo Report* **11**, 311–4.
- Görduysus MO, Görduysus M, Friedman S (2001) Operating microscope improves negotiation of second mesiobuccal canals in maxillary molars. *Journal of Endodontics* **27**, 683–6.
- Hsu YY, Kim S (1997) The resected root surface. The issue of canal isthmuses. *Dental Clinics of North America* **41**, 529–40.
- Kim S (1997) Principles of endodontic microsurgery. *Dental Clinics of North America* **41**, 481–97.
- Mines P, Loushine RJ, West LA, Liewehr FR, Zadinsky JR (1999) Use of the microscope in endodontics: a report based on a questionnaire. *Journal of Endodontics* **25**, 755–8.
- Rubinstein RA, Kim S (1999) Short-term observation of the results of endodontic surgery with the use of a surgical operation microscope and Super-EBA as root-end filling material. *Journal of Endodontics* **25**, 43–8.
- Rubinstein RA, Kim S (2002) Long-term follow-up of cases considered healed one year after apical microsurgery. *Journal of Endodontics* **28**, 378–83.
- Schwarze T, Baethge C, Stecher T, Geurtsen W (2002) Identification of second canals in the mesiobuccal root of maxillary first and second molars using magnifying loupes or an operating microscope. *Australian Endodontic Journal* **28**, 57–60.
- Sempira HN, Hartwell GR (2000) Frequency of second mesiobuccal canals in maxillary molars as determined by use of an operating microscope: a clinical study. *Journal of Endodontics* **26**, 673–4.
- Slaton CC, Loushine RJ, Weller RN, Parker MH, Kimbrough WF, Pashley DH (2003) Identification of resected root-end dentinal cracks: a comparative study of visual magnification. *Journal of Endodontics* **29**, 519–22.
- Stropko JJ (1999) Canal morphology of maxillary molars: clinical observations of canal configurations. *Journal of Endodontics* **25**, 446–50.
- Tam A, Yu DC (2002) Location of canal isthmus and accessory canals in the mesiobuccal root of maxillary first



- permanent molars. *Journal of Canadian Dental Association* **68**, 28–33.
- Teixeira FB, Sano CL, Gomes BPFA, Zaia AA, Ferraz CCR, Souza-Filho FJ (2003) A preliminary in vitro study of the incidence and position of the root canal isthmus in maxillary and mandibular first molars. *International Endodontic Journal* **36**, 276–80.
- Vertucci FJ (1984) Root canal anatomy of the human permanent teeth. *Oral Surgery, Oral Medicine and Oral Pathology* **58**; 589–99.
- Weller RN, Niemczyk SP, Kim S (1995) Incidence and position of the canal isthmus. Part 1. Mesio Buccal root of the maxillary first molar. *Journal of Endodontics* **21**, 380–3.